

# 琉球大学学術リポジトリ

## 食道および気管・気管支との位置関係に基づいた気管支動脈の解剖学的分類

メタデータ	言語: 出版者: 琉球大学 公開日: 2017-05-02 キーワード (Ja): キーワード (En): bronchial artery, esophagectomy, anatomy 作成者: 早坂, 研, Hayasaka, Ken メールアドレス: 所属:
URL	<a href="http://hdl.handle.net/20.500.12000/36548">http://hdl.handle.net/20.500.12000/36548</a>

学位論文

**A new anatomical classification of the bronchial arteries based on the spatial relationships to the esophagus and the tracheo-bronchus**

琉球大学大学院医学研究科医科学専攻

早坂 研



Ken Hayasaka<sup>1</sup>, Hajime Ishida<sup>2</sup>, Ryosuke Kimura<sup>2</sup>, Tadashi Nishimaki<sup>1</sup>

**Title: A new anatomical classification of the bronchial arteries based on the spatial relationships to the esophagus and the tracheo-bronchus**

<sup>1</sup> Department of Digestive and General Surgery, Graduate School of Medicine,  
University of the Ryukyus, 207 Uehara, Nishihara-cho, Okinawa 903-0215, Japan

<sup>2</sup> Department of Human Biology and Anatomy, Graduate School of Medicine,  
University of the Ryukyus, 207 Uehara, Nishihara-cho, Okinawa 903-0215, Japan

Address to reprints and correspondence: Ken Hayasaka, MD.

Department of Digestive and General Surgery, Graduate School of Medicine, University  
of the Ryukyus, 207 Uehara, Nishihara-cho, Okinawa 903-0215, Japan

E-mail: [kenh@xa3.so-net.ne.jp](mailto:kenh@xa3.so-net.ne.jp)

Tel: +81-98-895-1163

Fax: +81-98-895-1421

Article type: Original article (Experimental Original)

Keywords: bronchial artery, esophagectomy, anatomy

## **Abstract**

**Purpose:** To reveal the patterns of the mediastinal course of bronchial arteries (BAs).

**Methods:** The BAs were dissected to determine the positional relationships of their mediastinal courses with the tracheobronchus and the esophagus in 72 adult cadavers.

**Results:** The mediastinal courses of the 227 BAs found in the present study could be classified into 4 types. There were 61 and 163 BAs passing the right side (Type I) and the left side (Type II reaching dorsal surface (n = 98), or Type III reaching ventral surface (n = 65) of the tracheobronchus) of the esophagus, respectively. Three BAs originated from the subclavian artery (Type IV). All Type I BAs were the right BAs, whereas 91.8% of the Type II BAs were the left BAs. However, 43.1% and 56.9% of the Type III BAs were the right and left BAs, respectively.

**Conclusion:** The classification of the mediastinal course of the BAs determined by the spatial relationships to the tracheobronchus and the esophagus may be clinically useful because each category of this classification can be determined during esophagectomy, indicates whether the BA is a right or left BA.

## **Introduction**

*En bloc* esophagectomy with regional lymphadenectomy remains the mainstay treatment for resectable esophageal cancer [1], although, radiotherapy with or without chemotherapy has been used as the primary treatment in some cases of esophageal cancer. Some recent studies have reported that higher numbers of removed lymph nodes during esophagectomy are associated with better prognosis of esophageal cancer, suggesting the necessity of thorough lymphadenectomy [2, 3]. In contrast, surgical devascularization of the trachea and the main bronchi during extensive lymph node dissection sometimes results in tracheobronchial ulcers or fistulae due to tracheobronchial ischemia [4, 5]. Furthermore, high mortality rates have been reported in patients with such postoperative complications [6-8]. Therefore, precise dissection of lymph nodes while preserving the bronchial arteries (BAs) is mandatory for radical esophagectomy, and the knowledge of diverse patterns of branching and routes of the BAs is important for esophageal surgeons when performing radical esophagectomy. Moreover, the importance of the BAs has also been recognized in the field of lung transplantation and embolization for hemoptysis other than cancer surgery [9].

Recently introduced multi-detector row computed tomography (MDCT) with the computed tomography angiography enables the visualization of the running courses

of the BAs [10, 11]. According to the accumulation of imaging studies using MDCT, clinically useful information about the anatomy of the BAs including the precise site of the ostia on the thoracic aorta and positional relationships between the BAs and the esophagus or the tracheobronchus, has been revealed [12-17]. However, owing to the small number of anatomical cadaver studies of the BAs so far, whether all the BAs in individual patients can be fully visualized with MDCT remains unclear.

The aim of the present study is, therefore, 1) to precisely determine the numbers, the origins, the distributions, and the running course patterns of the right and the left BAs through a macro-anatomical study using cadavers; 2) to compare these data with the findings previously reported in MDCT studies; and 3) to provide surgeons with detailed anatomical features of the BAs for meticulous esophageal cancer surgery.

## **Materials and methods**

### *Cadavers*

We examined the anatomy of the BAs in 72 adult human cadavers at the University of the Ryukyus, Japan; 44 were men and 28 were women. Their age at the time of death ranged from 39 to 103 years. The mean age was 76.5 years. The most common cause of their death was malignant neoplasm (20 cases), followed by infection (19 cases) and cardiac disease (13 cases). This study was approved by the ethics committee of University of the Ryukyus (approval number: 885).

### *Dissection*

We detected the BAs macroscopically from the origin to the pulmonary root as follows. First, the anterolateral chest wall was removed. The pericardium was incised to remove the heart from the pericardial cavity. The hili of the lungs were transected with scissors to remove the right and the left lungs from the thoracic cavity. The pericardium was removed over the esophagus. The space between the thoracic aorta and the pulmonary trunk was dissected carefully to remove the pulmonary trunk without injuring the BAs. In this way, the deep mediastinal structures, including the thoracic aorta, the tracheobronchus, and the esophagus, were exposed. After the BAs passing ventral to the tracheobronchus were identified, dissection proceeded according to the process of



esophagectomy through right thoracotomy in esophageal cancer patients. The right side of the mediastinal pleura was removed followed by the resection of the azygos vein arch. At the hilus of the right lung, the BAs passing right side of the esophagus were identified. The esophagus was lifted from the thoracic aorta to identify the origins of the BAs passing the right side of the esophagus. The origins of the BAs from the thoracic aorta and passing the left side of the esophagus were also identified. The pathways of these arteries were confirmed by removing the left side of the mediastinal pleura. Dissection of the BAs was performed macroscopically with the surgical instruments for general use in surgery. The BAs less than 1mm in diameter were excluded in this study, because these arteries are generally not preserved in esophageal surgery.

The BA running along the right main bronchus was defined as the right BA, and the BA running along the left main bronchus was defined as the left BA.

#### *Recording the anatomical findings of the BAs*

##### *1) Number of the BAs*

The number of the BAs was determined as the number of their origins. In this study, we found two cases in which a single left BA originating from the thoracic aorta ran to divide into the ventral and dorsal branches of the trachea. We counted it as two left BAs originating from a common trunk of the proper BA.

## *2) Origin of the BAs*

Origins of the BAs were recorded as follows (Fig. 1): the thoracic aorta, the intercostal-bronchial trunk (IBT), the common trunk of the right and the left BAs (CTB), and the subclavian artery (SC). The level of origins of the BAs and the common trunks on the aorta have been evaluated by the vertebral level in the previous studies [11, 12, 18, 19]. However, it is difficult to compare the aortic level of the origins with the vertebral body from the narrow view of the surgical field. Therefore, we divided the thoracic aorta into four portions by the three cross-sections: the cross-section through the ductus arteriosus, the cross-section through the middle point of the origins of the first and the second aortic intercostal arteries, and the cross-section through the middle point of the origin of the second and the third aortic intercostal arteries. Thus, four parts of the aorta were defined as the aortic arch, the upper portion (U), the middle portion (M), and the lower portion (L), in order, from the proximal part (Fig.1).

## *3) Mediastinal courses of the BAs*

In the present study, we classified the mediastinal courses of the BAs into 4 types according to the positional relationships with the tracheobronchus and the esophagus (Fig. 2). The BA running anteriorly along the right side of the esophagus to reach the ventral or dorsal surface of the tracheobronchus was classified as Type I. The BA

running anteriorly along the left side of the esophagus to reach the dorsal surface of the tracheobronchus was classified as Type II. The BA running anteriorly along the left side of the esophagus, then passing the lateral side of the left main bronchus, to reach the ventral surface of the tracheobronchus was classified as Type III. The BA originating from the subclavian artery (SC) and descending to the ventral surface of the tracheobronchus was classified as Type IV. We could apply the running courses of all the BAs found in the 72 cadavers to this classification.

#### *4) Distributions of the BAs*

Based on the Kasai's [20] report suggesting the presence of anatomical relationships between the origin and the distribution of the BAs, we examined the distribution patterns at the pulmonary hilus to clarify the presence or absence of relationships between the distribution and the mediastinal course of the BAs. The distributions of the BAs at the pulmonary hilus were classified into the superior branch (S), the superior and inferior branch (SI), and the inferior branch (I).

## **Results**

### *1) Number of the BAs*

We identified 100 right and 127 left BAs in the 72 cadavers. The numbers of the BAs per cadaver ranged from 1 to 5 (mean: 3.15). The mean number of the right and the left BAs was 1.39 and 1.76, respectively, per cadaver. Cadavers with one right and two left BAs were the most commonly observed (38.9%), followed by cadavers with two right and two left BAs (18.1%) (Table 1). There were two cadavers (2.8%) in which either of the right or the left BA was absent. The right BA was absent in one cadaver, and the left BA was absent in another cadaver (Table 1).

### *2) Origins of the BAs*

Of the 100 right BAs, 60 (60%), 28 (28%), 9 (9%), 2 (2%), and 1 (1%) originated from the right intercostal- bronchial trunk (IBT), the common trunk of the right and the left BAs (CTB), the thoracic aorta, the right SC, and the left SC, respectively (Fig. 3). Of the 127 left BAs, 98 (77.2%) and 29 (22.8%) originated from the thoracic aorta and the CTB, respectively (Fig. 4). The cadavers with one right BA from the right IBT and two left BAs from the thoracic aorta were most commonly observed (20 bodies, 27.8%), followed by the cadavers with one right BA from the right IBT and one left BA from the thoracic aorta (9 bodies, 12.5%), and the cadavers with two right BAs from the right

IBT or CTB, and two left BAs from the thoracic aorta or CTB (8 bodies, 11.1%) (Table 1).

There were 192 arteries originating directly from the thoracic aorta (2.67/body). Of the 192 arteries, 59 (30.7%), 28 (14.6%), 9 (4.7%), and 96 (50%) were the IBTs, the CTBs, the right BAs, and the left BAs, respectively. Two right BAs originating from 1 IBT, 2 left BAs from 1 CTB, and 2 left BAs from 1 proper BA were found in 1, 1, and 2 cadavers, respectively. Of the 192 arteries including 105 proper BAs and 87 common trunks, 164 (85.4%) originated from the U or M portion. Only 4 arteries (2.1%), including 2 right BAs and 2 CTBs, originated from the aortic arch. The remaining 24 arteries (12.5%) originated from the L portion of the thoracic aorta, including 21 left BAs and 3 CTBs.

### *3) Mediastinal courses of the BAs*

Of the 227 BAs, Types I, II, III, and IV were found in 61 (26.9%), 98 (43.2%), 65 (28.6%), and 3 (1.3%), respectively. However, Types I, II, III, and IV were present in 60 (83.3%), 63 (87.5%), 44 (61.1%), 3 (4.2%) of the 72 cadavers, respectively. Of the 61 arteries showing Type I, 59 (96.7%) were the right BAs from the IBT, and the remaining two were the right BAs originating directly from the thoracic aorta (Fig. 3). Thus, all of the arteries showing Type I were right BAs. Of the 98 arteries showing Type II, 8

(8.2%), 76 (77.5%), and 14 (14.3%) were the right BAs from the CTB, the left BAs from the thoracic aorta, and the left BAs from the CTB, respectively (Fig. 3,4). Of the 127 left BAs, 90 (70.9%) showed the Type II course (Fig. 4). Particularly, all of the left BAs from the L portion ran along this course. Of the 65 arteries showing Type III, 7 (10.8%), 20 (30.8%), and 1 (1.5%) were the right BAs originating from the thoracic aorta, the CTB, and the IBT, respectively (Fig. 3). However, 22 (33.8%), and 15 (23.1 %) were the left BAs from the thoracic aorta, and the CTB, respectively (Fig. 4). Thus, the 65 arteries of Type III were composed of 28 right BAs (43.1%), and 37 left BAs (56.9%). All of the BAs originating from the aortic arch showed the Type III pattern. Of the 3 Type IV arteries, two and one were the right BAs from the right SC and the left SC, respectively (Fig. 3). Any BAs showing mediastinal courses not applicable to this classification were not found. All of the BAs originating from the thoracic aorta, to reach the ventral surface of the tracheobronchus, passed the lateral side of the right or the left main bronchi. Of the 28 CTBs, 20 arteries branched out into the right and left BAs showing the same running course category: the Type II (n=7), and the Type III (n=13) courses. The remaining 8 arteries branched out into the right and left BAs showing different running course categories: one CTB had one right BA showing the Type II with one left BA showing the Type III, and 7 CTBs had one right BA

showing the Type III with one left BAs showing the Type II.

#### *4) Distribution of the BAs*

The mediastinal courses of the BAs were related to their distributions. Of the 61 right BAs showing Type I, 59 (96.7%) had the superior branches (S or SI) (Fig. 3). However, all the right BAs showing Type II, and 24 (85.7%) right BAs showing Type III had the inferior branches (SI or I) (Fig 3). In contrast with the right BAs, 35 (94.6%) of the 37 left BAs showing Type III, had the superior branches (Fig. 4).

## **Discussion**

The BAs constitute the nutritive vascular system of the pulmonary tissues (the bronchial walls and the glands, walls of the large vessels, and the visceral pleura). There are many variations in the number, the origin, and the course of the BAs [18-21]. The underlying anatomical study of the BAs was conducted by Cauldwell et al in 1948 [18]. After an anatomical investigation in 150 cadavers, they have reported the classification of the branching patterns of the BAs based on the origin and the number of the right and the left BAs. In their study, the most commonly encountered pattern was the combination of one right BA originating from the right IBT and two left BAs originating from the thoracic aorta. After their report, this pattern has been described as normal in many standard textbooks of anatomy and thoracic surgery. However, there are more anatomical variations of the BAs taking into account the mediastinal courses and the distributions as shown in this study. Those previous studies have classified the BAs into 9 or more subtypes based on the numbers, origins, and the branching patterns of this artery. In contrast with such complex classifications of the BAs, we made the simple classification of the BAs, based on the spatial relationships to the tracheobronchus and the esophagus. Our classification is composed of the 4 categories (Type I-IV). However, any BAs not applicable to this classification were not found in the present study. Thus,



our classification may be more convenient in the clinical practice, particularly during esophageal surgery.

The BAs that originate outside the segment of the aorta between the T5 and T6 vertebrae are defined as ectopic in the prior studies [12]. Ectopic BAs include the BAs originating from the aortic arch, the subclavian artery, the descending aorta, the brachiocephalic trunk, the thyrocervical trunk, the internal mammary artery, and the coronary artery. The frequencies of the right and the left ectopic BAs have been reported to range from 14.0% to 17.2%, and 11.6% to 20.0%, respectively [12-14]. However, it is difficult to compare the aortic level of the BA origin with the vertebral body in the narrow view of the surgical field. Therefore, we divided the aorta into 4 portions using the ductus arteriosus and the aortic origins of the intercostal arteries: the aortic arch, upper (U), middle (M), and lower (L) portions. In this classification, the U and M portions corresponded to the segment of the aorta between the T5 and T6 vertebrae. By the aforementioned definition of the ectopic BA, i.e., the BAs originating outside the U and M portion, 10 right BAs (10%) and 27 left BAs (21.3%) are regarded as ectopic in our study. These frequencies found in the present study are consistent with those reported by the previous studies.

We found more variations in the right BAs than in the left BAs. Embryological

development of the BAs may explain this phenomenon. Boyden dissected fetuses and found that the BAs appear between the 9th and 12th week, and develop long after the bronchopulmonary segments and their pulmonary arterial supply have been established [22,23]. The BAs develop after the positional relationships of the aorta, the tracheobronchus, and the esophagus were determined. As a result, the BAs extend depending on favorable juxtaposition in each individual. Since the left main bronchus crosses the aorta closely, the distance between the right main bronchus and the aorta is larger than that between the left main bronchus and the aorta. Therefore, larger distance from the aorta to the right main bronchus may allow the development of more variations of the right BA as compared with the left BA. Boyden [23] also stated that the first BA appears as the tracheobronchial artery which arises from the aorta just below the level of the ductus arteriosus, and ascends between the aorta and the esophagus to reach the ventral surface of the tracheobronchus supplying blood to the trachea and the proximal parts of the right and the left main bronchus. This artery has a type III course in our classification, which is the common type of the right BAs from the thoracic aorta and the CTBs. The right BAs from the IBT and the left BAs from the thoracic aorta, which is the most common branching pattern, develop later than the tracheobronchial artery [23]. In our study, the cadavers without the right BAs from the IBT mostly have right

BAs from the CTB or the thoracic aorta (Table 1). We speculate that the tracheobronchial artery may be persistent as the right BA, when the right BAs from the IBT did not develop sufficiently.

Recent advancement of imaging technology enabled the BAs to be depicted in a living body [10,11]. MDCT is one of such modality and is routinely used in clinical practice. Anatomical characteristics of the right and the left BAs have been also reported using MDCT [13-17]. The findings of the representative MDCT studies of the BA anatomy are summarized in Table2, together with those from the cadaver dissection studies [18,19], including the present study. The mean numbers of the right BAs per body do not seem to be different among the 8 studies including 5 MDCT studies and 3 cadaver dissection studies. However, the mean numbers (0.95 – 1.44) of the left BAs per body in the MDCT studies seem smaller than those (1.76 – 1.9) observed in the cadaver dissection studies. Furthermore, the mean numbers of the left BA were smaller than those of the right BA in all of the 5 MDCT studies. In contrast with the MDCT studies, the former numbers are greater than the latter numbers in all of the 3 cadaver dissection studies. As clearly shown in the Table2, the discrepancy in the mean number of the left BA is mainly attributed to the smaller numbers (0.65 – 0.86) of the left BA originating from the thoracic aorta in the MDCT studies as compared with those (1.36 –

1.46) found in the cadaver dissection studies. The numbers in the former studies are almost half of those in the latter studies. These results indicate the tendency of MDCT studies to underestimate the actual number of the left BAs. The shorter course of the left BA and the beating movement of the heart may preclude clear visualization of the left BA in MDCT studies.

In the present study, running courses of the BAs were classified into 4 types, and all courses of the BAs observed in the present study were applicable to this classification. All of the BAs passing the right side of the esophagus (Type I ) were the right BAs, whereas, not all BAs passing the left side of the esophagus (Type II and Type III ) were the left BAs. Of the 98 BAs showing the Type II course, 8 (8.2%) were the right BAs. Of the 65 BAs showing the Type III course, 28 (43.1%) were the right BAs. Thus, of the 163 BAs passing the left side of the esophagus, 36 (22.1%) were the right BAs. The origin and the distribution of the BAs cannot be always identified during esophagectomy. However, the running courses of the BAs determined by the spatial relationships to the tracheobronchus and the esophagus can be easily identified even in the narrow surgical field. Thus, the classification of the running courses of BAs may be clinically of use as compared with the classification determined by the origin and distribution of the BA. Moreover, the present study revealed the relationships between

the mediastinal courses and the distribution at the pulmonary hilus of the BAs.

In conclusion, the present study revealed more detailed anatomical variations of the bronchial arteries using the three parameters including the origin, the distribution, and the mediastinal running course of the artery. The number of the left bronchial artery may be underestimated in the MDCT studies. The classification of the running course of the bronchial artery determined by the spatial relationships to the tracheobronchus and the esophagus may be clinically of use because this classification can be easily applied during radical esophagectomy for esophageal cancer and each category of the classification implies the possibilities of the right or left bronchial arteries in the surgical field during esophagectomy.

**Acknowledgments:** The authors appreciate the contribution of the Deigo-Kai, voluntary body donation organization of University of the Ryukyus, for allowing the macro-anatomical study using the cadavers.

**Conflict of interest:** There is no conflict of interest.

## References

1. Nishimaki T, Shimoji H, Sunagawa H. Recent changes and the future roles of esophageal cancer surgery. *Ann Thorac Cardiovasc Surg.* 2004; 10:324–32
2. Peyre CG, Hagen JA, DeMeester SR, Altorki NK, Ancona E, Griffin SM, et al. The number of lymph nodes removed predicts survival in esophageal cancer: an international study on the impact of extent of surgical resection. *Ann Surg.* 2008; 248:549–56.
3. Altorki NK, Zhou XK, Stiles B, Port JL, Paul S, Lee PC, et al. Total number of resected lymph nodes predicts survival in esophageal cancer. *Ann Surg.* 2008; 248:221–6.
4. Maruyama K, Motoyama S, Sato Y, Hayashi K, Usami S, Minamiya Y, et al. Tracheobronchial lesions following esophagectomy: erosions, ulcers, and fistulae, and the predictive value of lymph node-related factors. *World J Surg.* 2009; 33:778–84.
5. Katayama H, Kurokawa Y, Nakamura K, Ito H, Kanemitsu Y, Masuda N, et al. Extended Clavien-Dindo classification of surgical complications: Japan Clinical Oncology Group postoperative complications criteria. *Surg. Today.* 2016; 46:668–85.
6. Matsuda S, Niihara M, Tsubosa Y, Sato H, Takebayashi K, Kawamorita K, et al. Clinical significance of postoperative recovery of serum albumin levels in patients with

esophageal cancer who underwent transthoracic esophagectomy. *Surg. Today*. 2016; 46:1138–45.

7. Kato F, Takeuchi H, Matsuda S, Kawakubo H, Omori T, Kitagawa Y. Incidence of and risk factors for venous thromboembolism during surgical treatment for esophageal cancer: a single-institution study. *Surg. Today*. 2016; 46:445–52.

8. Bartels HE, Stein HJ, Siewert JR. Tracheobronchial lesions following oesophagectomy: Prevalence, predisposing factors and outcome. *Br J Surg*. 1998; 85:403–6.

9. Osiro S, Wear C, Hudson R, Ma X-X, Zurada A, Michalak M, et al. A friend to the airways: a review of the emerging clinical importance of the bronchial arterial circulation. *Surg Radiol Anat*. 2012; 34:791–8.

10. Murayama S, Hashiguchi N, Murakami J, Sakai S, Matsumoto S, Mizushima A, et al. Helical CT imaging of bronchial arteries with curved reformation technique in comparison with selective bronchial arteriography: preliminary report. *J Comput Assist Tomogr*. 1996; 20:749–55.

11. Remy-jardin M, Dumont P, Brillet P, Bruzzi J, Remy J. Bronchial and nonbronchial systemic arteries at multi-detector row CT angiography: comparison with conventional angiography. *Radiology*. 2004; 233:741–9.



12. Hartmann IJ, Remy-Jardin M, Menchini L, Teisseire A, Khalil C, Remy J. Ectopic origin of bronchial arteries: assessment with multidetector helical CT angiography. *Eur Radiol.* 2007; 17:1943–53.
13. Morita Y, Takase K, Ichikawa H, Yamada T, Sato A, Higano S, et al. Bronchial artery anatomy: preoperative 3D simulation with multidetector CT. *Radiology.* 2010; 255:934–43.
14. Battal B, Akgun V, Karaman B, Bozlar U, Tasar M. Normal anatomical features and variations of bronchial arteries: an analysis with 64-detector-row computed tomographic angiography. *J Comput Assist Tomogr.* 2011; 35:253–9.
15. Ziyawudong J, Kawai N, Sato M, Ikoma A, Sanda H, Takeuchi T, et al. Aortic ostia of the bronchial arteries and tracheal bifurcation: MDCT analysis. *World J Radiol.* 2012; 4:29–35.
16. Wada T, Takeuchi H, Kawakubo H, Nakamura R, Oyama T, Takahashi T, et al. Clinical utility of preoperative evaluation of bronchial arteries by three-dimensional computed tomographic angiography for esophageal cancer surgery. *Dis Esophagus.* 2013; 26:616–22.
17. Yener Ö, Türkvatan A, Yüce G, Yener AÜ. The normal anatomy and variations of the bronchial arteries: evaluation with multidetector computed tomography. *Can Assoc*

Radiol J. 2015; 66:44–52.

18. Cauldwell EW, Siekert RG. The bronchial arteries; an anatomic study of 150 human cadavers. *Surg Gynecol Obstet.* 1948; 86:395–412.

19. Liebow AA. Patterns of origin and distribution of the major bronchial arteries in man. *Am J Anat.* 1965; 117:19–32.

20. Kasai T, Chiba S. Macroscopic anatomy of the bronchial arteries. *Anat Anz.* 1979; 145:166–81.

21. Nakamura N. Zur anatomie der bronchialarterien. *Anat Anz.* 1924; 58:508–17.

22. Boyden EA. The time lag in the development of bronchial arteries. *Anat Rec.* 1970; 166:611–4.

23. Boyden EA. The developing bronchial arteries in a fetus of the twelfth week. *Am J Anat.* 1970; 129:357–68.

**Table 1** Number and origins of the bronchial arteries (BAs) in 72 cadavers

Total number of the BAs	Right BA		Left BA		Number of the cadavers (%)
	Number	Origin	Number	Origin	
1	0	/	1	Aorta	1 (1.4)
	1	IBT	0	/	1 (1.4)
2	1	IBT <sup>a</sup>	1	Aorta	9 (12.5)
	1	CTB	1	CTB	2 (2.8)
	1	Aorta	1	Aorta	1 (1.4)
3	1	IBT	2	Aorta×2 <sup>b</sup>	20 (27.8)
	1	CTB	2	Aorta, CTB	4 (5.6)
	1	Aorta <sup>c</sup>	2	Aorta×2	3 (4.2)
	1	Right SC	2	Aorta×2	1 (1.4)
	2	IBT, CTB	1	CTB	5 (6.9)
	2	IBT×2 <sup>d</sup>	1	Aorta	2 (2.8)
	2	IBT, Aorta	1	Aorta	2 (2.8)
4	1	IBT	3	Aorta×3 <sup>e</sup>	1 (1.4)
	1	CTB	3	Aorta×2, CTB	1 (1.4)
	2	IBT, CTB	2	Aorta, CTB	8 (11.1)
	2	IBT, aorta	2	Aorta×2	2 (2.8)
	2	IBT, CTB	2	Aorta, CTB	1 (1.4)
	2	IBT, CTB	2	CTB×2 <sup>f</sup>	1 (1.4)
	2	IBT, Left SC	2	Aorta×2	1 (1.4)
5	2	IBT, CTB	3	Aorta×2, CTB	4 (5.6)
	2	CTB, Right SC	3	Aorta×2, CTB	1 (1.4)
	3	IBT, Aorta, CTB	2	Aorta, CTB	1 (1.4)

IBT: the intercostal- bronchial trunk, CTB: the common trunk of the right and the left

BAs, SC: the subclavian artery

<sup>a</sup>The right BA passing type III course: 1case, <sup>b</sup>Two left BAs originating from one

proper BA: 1case, <sup>c</sup>The right BAs passing type I course: 2 cases, <sup>d</sup>Two right BAs

originating from one IBT: 1 case, <sup>e</sup> Two left BAs originating from one proper BA, <sup>f</sup> Two  
left BAs originating from one CTB

**Table 2** Comparison of the anatomical features of the bronchial artery between MDCT studies and cadaver dissection studies

Research modality	MDCT					Cadaver dissection		
	Morita [13]*	Battal [14]*	Ziyawudong [15]*	Wada [16]*	Yener [17]*	Cauldwell [18]*	Liebow [19]*	Present study
No. of bodies	73	163	100	64	208	150	50	72
<b>Right BA</b>								
Total No.	118	229	132	69	291	203	89	100
No./body	1.62	1.4	1.32	1.08	1.4	1.35	1.78	1.39
<b>Origin</b>								
IBT	0.84	0.64	0.69	0.64	0.67	0.91	/	0.83
CTB	0.52	0.47	0.34	0.13	0.37	0.27	/	0.39
TA	0.21	0.25	0.28	0.27	0.31	0.16	/	0.13
Other	0.05	0.05	0.01	0.05	0.05	0.01	/	0.04
<b>Left BA</b>								
Total No.	105	203	103	61	240	264	95	127
No./ body	1.44	1.25	1.03	0.95	1.15	1.76	1.9	1.76
<b>Origin</b>								
IBT	0.05	0.01	0.04	0.02	0.08	0.00	/	0.00
CTB	0.52	0.47	0.34	0.09	0.37	0.29	/	0.40
TA	0.86	0.75	0.65	0.84	0.70	1.46	/	1.36
Other	0.00	0.01	0.00	0.00	0.01	0.01	/	0.00

BA: the bronchial artery, MDCT: multi-detector row computed tomography, No.:

number, IBT: the intercostal-bronchial trunk, CTB: the common trunk of the right and

the left BAs, TA: the thoracic aorta

\*The numbers in square brackets indicate the references.

## **Legends**

*Fig. 1* Classification of origins of the bronchial arteries (BAs).

Origins of the BAs were classified as the thoracic aorta, the intercostal- bronchial trunk (IBT), the common trunk of the right and the left BAs (CTB) and the subclavian artery (SC).

We divided the thoracic aorta into four portions by the three cross-sections: the cross-section through the ductus arteriosus, the cross-section through the middle point of the origins of the first and the second aortic intercostal arteries (ICs), and the cross-section through the middle point of the origin of the second and the third aortic ICs. Thus, four parts are defined as the aortic arch, the upper portion (U), the middle portion (M), and the lower portion (L), in order, from the proximal part. \*The ductus arteriosus

*Fig. 2* Classification of the running courses of the bronchial arteries (BAs).

The mediastinal courses of the BAs were classified into 4 types according to the positional relationships with the tracheobronchus and the esophagus. Type I: The BAs running anteriorly along the right side of the esophagus. Type II: The BAs running anteriorly along the left side of the esophagus to reach the dorsal surface of the tracheobronchus. Type III: The BAs running anteriorly along the left side of the

esophagus, and then passing the lateral side of the left main bronchus to reach the ventral surface of the tracheobronchus. Type IV: The BAs originating from the SC to descend the ventral surface of the tracheobronchus. Ao, Br, and E indicates the aorta, bronchus, and esophagus, respectively.

*Fig. 3* Number, origins, and distributions of the right bronchial arteries (BAs) according to the classification of the running courses of the BAs (n=100).

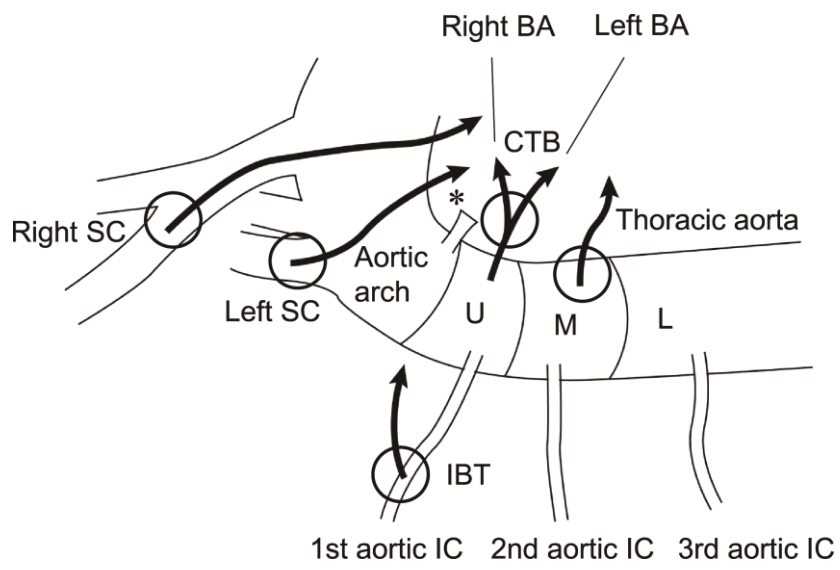
IBT: the intercostal-bronchial trunk, TA: the thoracic aorta, CTB: the common trunk of the right and the left BAs, SC: the subclavian artery, S: the superior branch, SI: the superior and inferior branch, I: the inferior branch

\*Two right BAs originating from one IBT were found in one body.

*Fig. 4* Number, origins, and distributions of the left bronchial arteries (BAs) according to the classification of the running courses of the BAs (n=127).

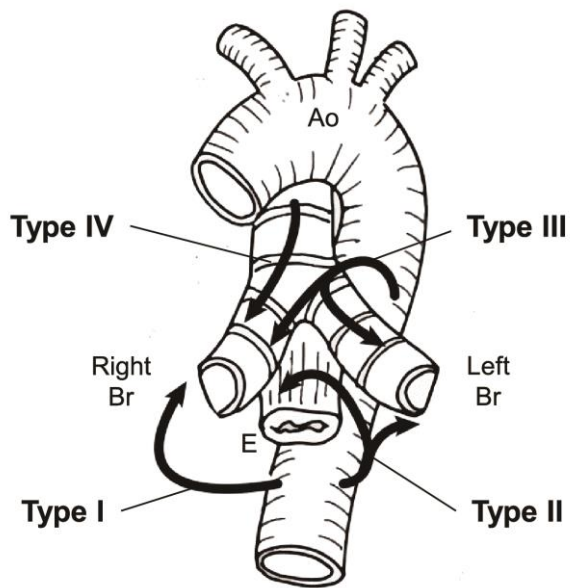
TA: the thoracic aorta, CTB: the common trunk of the right and the left BAs, S: the superior branch, SI: the superior and inferior branch, I: the inferior branch

<sup>a</sup>Two left BAs originating from one proper BA, <sup>b</sup>two left BAs originating from one CTB, and <sup>c</sup>two left BAs originating from one proper BA were found in 1, 1, and 1 body, respectively.

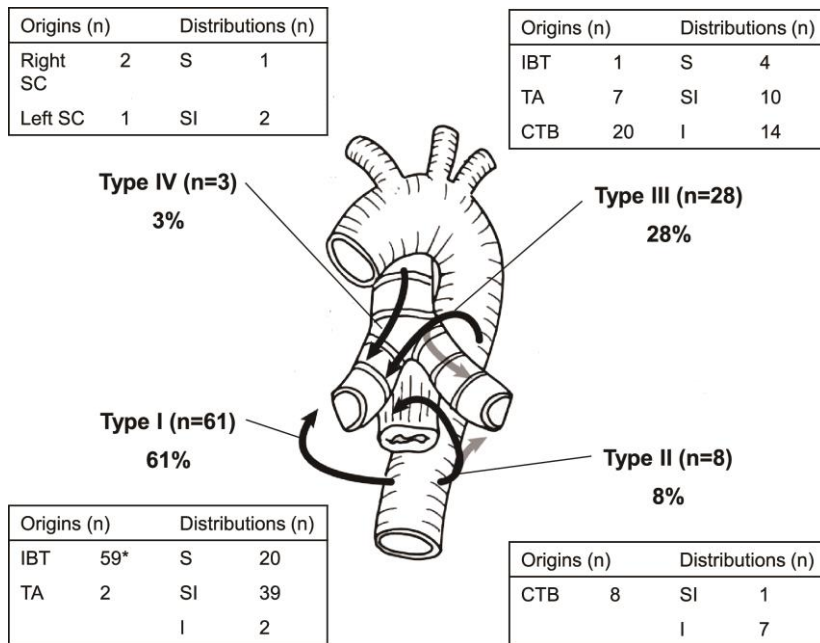


**Figure 1**

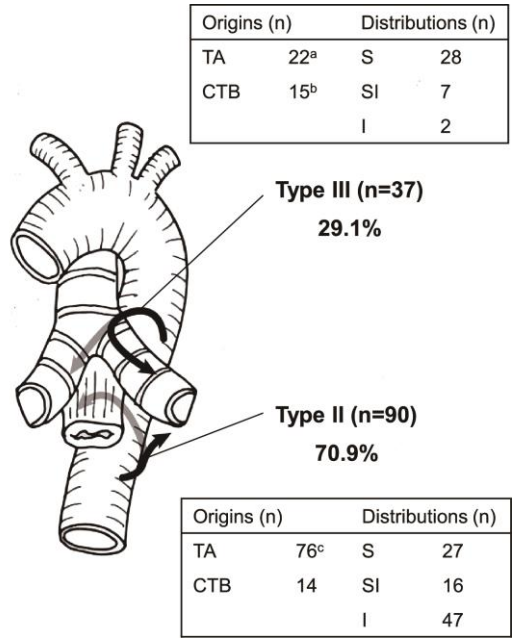




**Figure 2**



**Figure 3**



**Figure 4**