

## Elsberg Syndrome with Eosinophilic Meningoencephalitis Caused by *Angiostrongylus cantonensis*

Makoto Furugen<sup>1</sup>, Shin Yamashiro<sup>1</sup>, Maki Tamayose<sup>1</sup>, Yui Naha<sup>1</sup>, Kazuya Miyagi<sup>1</sup>,  
Chikara Nakasone<sup>1</sup>, Teruhito Uchihara<sup>1</sup>, Shusaku Haranaga<sup>1</sup>, Masato Azuma<sup>1</sup>,  
Satomi Yara<sup>1</sup>, Takashi Shinzato<sup>3</sup>, Futoshi Higa<sup>1</sup>, Hiromu Toma<sup>2</sup>,  
Masao Tateyama<sup>1</sup> and Jiro Fujita<sup>1</sup>

---

### Abstract

---

A 42-year-old man was admitted to our hospital with a history of fever, headache and disorientation. His cerebrospinal fluid revealed eosinophilia and his serum had an antibody against *Angiostrongylus cantonensis* (*A. cantonensis*). Then, he was diagnosed as eosinophilic meningoencephalitis caused by *A. cantonensis*. He was treated with repeated lumbar punctures and oral prednisolone. Although a symptom he had been suffering from at the time of his admission was urinary retention, this symptom disappeared as his general condition improved. Therefore his case was considered to be Elsberg syndrome with eosinophilic meningoencephalitis caused by *A. cantonensis*.

**Key words:** eosinophilic meningoencephalitis, *Angiostrongylus cantonensis*, Elsberg syndrome

(DOI: 10.2169/internalmedicine.45.1871)

---

### Introduction

---

*Angiostrongylus cantonensis* (*A. cantonensis*) is the most common cause of eosinophilic meningitis worldwide (1). The major intermediate hosts are the African giant snail (*Achutina fulica*) and the golden apple snail (*Ampullarium canaliculatus*) (2). Humans become infected through the consumption of raw snails, fresh water or vegetables contaminated with intermediate hosts or carrier hosts. The third-stage larvae are transported to the central nervous system where they incite eosinophilic meningitis with symptoms including headache, fever and neck stiffness (1). On the other hand, cases with transient urinary retention caused by aseptic meningitis accompanied with spinal cord disorder are known as Elsberg syndrome (3-7). We present herein a case of Elsberg syndrome with eosinophilic meningoencephalitis caused by *A. cantonensis*.

---

### Case Report

---

A 42-year-old man presented to our hospital with a 1-week history of high fever, headache, vomiting, visual hallucination and disorientation. At the previous hospital, he had been administered a treatment of aciclovir and dexamethasone for suspected viral meningoencephalitis, but his symptoms had been getting worse. He was admitted to our hospital. He had a past history of infantile asthma, and his occupation was a cook.

On admission, his consciousness level was score 2 when using the Japan Coma Scale and 14 points when using the Glasgow Coma Scale (eye opening 4, best verbal response 4, and best motor response 6). Neurological examinations concerning his cranial nerves were normal, however, mild neck stiffness was detected. Concerning his motor system, he had an intention tremor in both of his upper limbs. His muscle tonus, muscle force and cooperation were normal.

---

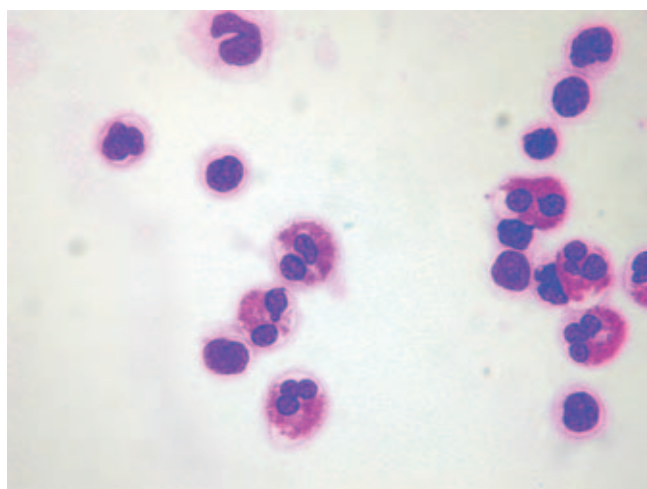
<sup>1</sup> Department of Medicine and Therapeutics, Control and Prevention of Infectious Diseases (First Department of Internal Medicine), Faculty of Medicine, University of the Ryukyus, Okinawa, <sup>2</sup> Department of Tropical Parasitology, Graduate School of Medicine, University of the Ryukyus, Okinawa and <sup>3</sup> Nakagami Hospital, Okinawa

Received for publication May 1, 2006; Accepted for publication August 22, 2006

Correspondence to Dr. Makoto Furugen, the First Department of Internal Medicine, Faculty of Medicine University of the Ryukyus, 207 Uehara, Nishihara-cho, Nakagami-gun, Okinawa 903-0215

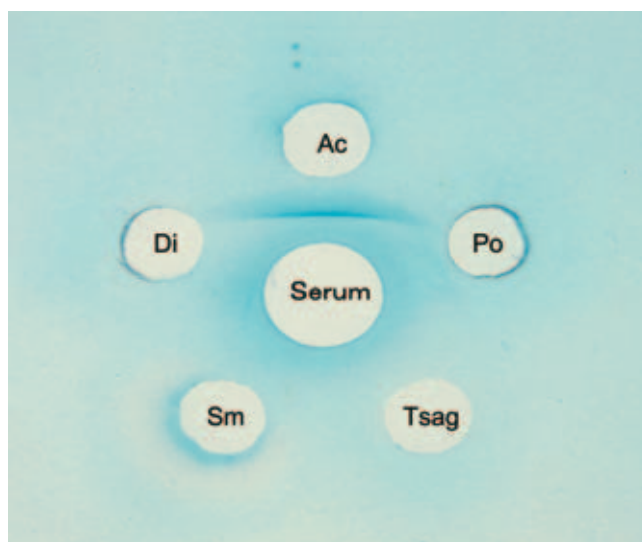
**Table 1. Laboratory Data**

CBC		Blood chemistry		Serum	
WBC	3200 /mm <sup>3</sup>	TP	6.9 g/dl	CRP	0.38 mg/dl
Stab	2.0 %	ALB	4.6 g/dl	Cerebrospinal Fluid Examination	
Seg	81.0 %	GLU	119 mg/dl	Pressure	19 cmH <sub>2</sub> O
Lymp	13.0 %	BUN	14 mg/dl	View	Clear
Mono	2.0 %	CRE	0.77 mg/dl	Cell Number	237 /mm <sup>3</sup>
Eos	1.0 %	Na	138 mEq/l	Eosinophil cell	23 /mm <sup>3</sup>
Atypical lymph	1.0 %	K	4.5 mEq/l	Mononuclear cell	214 /mm <sup>3</sup>
RBC	412 × 10 <sup>4</sup> /mm <sup>3</sup>	Cl	99 mEq/l	Protein	328 mg/dl
HGB	13.5 g/dl	Ca	9.7 mg/dl	Glucose	38 mg/dl
HCT	38.1 %	T.Bil	0.5 mg/dl	Culture	negative
PLT	17.1 × 10 <sup>4</sup> /mm <sup>3</sup>	AST	16 IU/l (aspartate aminotransferase)		
ESR	11 mm/h	ALT	17 IU/l (alanine aminotransferase)		
		ALP	154 IU/l		
		LDH	38 IU/l		
		γ-GTP	38 IU/l		
		CPK	53 IU/l		
		AMY	111 IU/l		

**Figure 1. Eosinophils in the cerebrospinal fluid (HE stain, ×1000).**

His deep tendon reflexes were exaggerated, but there was no difference between right and left limbs. Pathological reflexes were negative. As a sensory disorder, a paresthesia; a severe pain even with the soft touch of his extremities, was observed. Standing and gait disturbances were not seen. As an autonomic dysfunction, urinary retention was noted. He had a loss of urinary sensation and could hardly urinate by himself. Urinary incontinence was not seen, and about one liter of urine was removed from his bladder by using a catheter. Disturbance of defecation was not found. Laboratory findings on admission showed a white blood cell count of 3,200 cells/mm<sup>3</sup> with 1.0% eosinophils, C - reactive protein (CRP) of 0.38 mg/dl, erythrocyte sedimentation rate of 11 mm/hour and almost normal biochemical examinations (Table 1). A chest roentgenogram showed normal findings. Also, the blood culture examinations were negative. Although the evaluation was difficult because of motion artifacts, a brain magnetic resonance image and an electroencephalography showed no significant findings.

After he was admitted to our hospital, a lumbar puncture was performed, and his cerebrospinal fluid showed eosino-

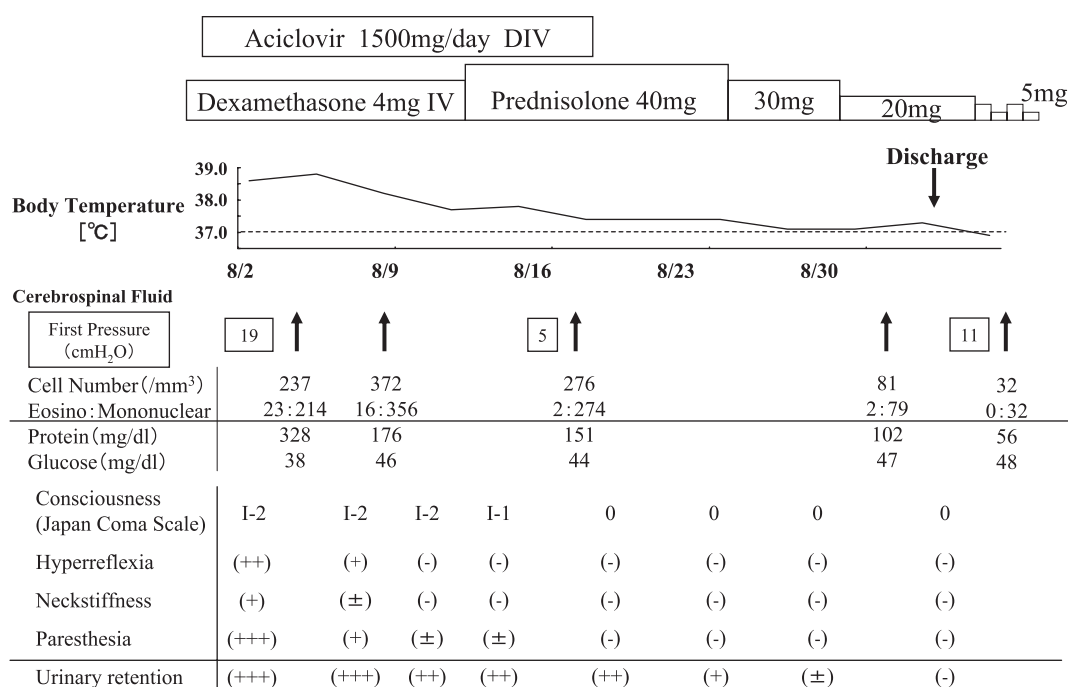
**Figure 2. Double immunodiffusion of the patient's serum, showing positivity for *Angiostrongylus cantonensis* antibody. Ac: *Angiostrongylus cantonensis* antigen, Po: *Paragonimus ohirai* antigen. Di: *Dirofilaria immitis* antigen, Sm: *Sparganum mansoni* antigen. Tsag: *Cysticercus cellulosae* antigen.**

philia (9.7%, 23/mm<sup>3</sup>) (Table 1) (Fig. 1). Therefore, he was diagnosed as eosinophilic meningoencephalitis according to Kuberski's criteria (8). To examine the cause of eosinophilic meningoencephalitis, an antibody test against helminth was performed using double immunodiffusion. Since his serum contained an antibody against *A. cantonensis* (Fig. 2), *A. cantonensis* was considered to be the causative agent. He was treated with oral prednisolone (40 mg/day) instead of intravenous dexamethasone (4 mg/day), which had been started by the previous doctor. During the clinical course, his symptoms such as high fever, headache, disorientation, neck stiffness, hyperreflexia and paresthesia of his limbs improved gradually within two weeks from his admission. His urinary sensation and self-urination were also improving from one week after his admission. In addition, his urinary retention was recovered completely about a month after his admission (Fig. 3). Judging from his clinical course, urinary retention was considered to be a sign of eosinophilic meningoencephalitis.

Although prednisolone was gradually reduced, his symptoms did not relapse. Total cell number and eosinophils in the cerebrospinal fluid also decreased gradually (Fig. 3).

## Discussion

Eosinophilic meningitis is defined by the presence of 10 or more eosinophils/mm<sup>3</sup> in the cerebrospinal fluid or eosinophilia of at least 10% of the total cerebrospinal fluid leukocyte count (8). The common causes of the eosinophilic meningitis are an infection by a helminthic parasite, such as *A. cantonensis*, *Gnathostoma spinigerum*, *Baylisascaris procyonis*, or *Coccidioides immitis*, another noninfec-



**Figure 3.** Clinical course.

tious condition for idiopathic hypereosinophilic syndrome, medication and Hodgkin's disease. Of these, *A. cantonensis* is the most common cause of eosinophilic meningitis (1). In this case, the patient had 23 eosinophils/mm<sup>3</sup> (9.7%) in his cerebrospinal fluid, even though he had been treated by intravenous dexamethasone. In the eosinophilic meningitis caused by *A. cantonensis*, peripheral blood eosinophilia was reported in two-thirds of patients (1). However, the present case did not show peripheral blood eosinophilia even before treatment with dexamethasone.

*A. cantonensis*, the rat lung worm, is an infection occurring primarily in Southeast Asia and throughout the Pacific Basin, including Hawaii, Indonesia, the Philippines, Japan and Papua New Guinea. Humans are infected through the consumption of raw snails, fresh water and vegetables contaminated with intermediate hosts or carrier hosts. In humans, the third-stage larvae are transported via the blood stream to the central nervous system where they burrow into the neural tissue, inciting an inflammatory response that eventually kills the parasites (1).

In *A. cantonensis* infection, headache, neck stiffness and visual disturbance are common symptoms, but fever is seen in less than half of the patients. In addition, paresthesia of the extremities, trunk or face are the most distinctive neurological finding (1). In this case, a paresthesia was seen, which was a severe pain at the soft touch of his extremities.

Otherwise, cases of transient urinary retention caused by radiculopathy in aseptic meningitis have been reported, which is well known as Elsberg syndrome (3-7). In this case, the patient had urinary retention since eosinophilic meningitis manifested. After steroid therapy, the symptoms of urinary retention ameliorated, accompanying improve-

ment of his general state. This suggested that he had Elsberg syndrome caused by eosinophilic meningoencephalitis. Although urinary retention accompanying eosinophilic meningitis caused by *A. cantonensis* has been reported in a few pediatric cases (9), this was the first case with an adult. In this patient, since the uroflowmetry could not be examined because of his disquietude and dis cooperation, the causative site of neurogenic bladder was unclear. However, due to the absence of a reflex bladder, we considered it to be a nuclear and infranuclear disorder rather than a supranuclear disorder with detrusor sphincter dyssynergia. In the previous 87 reported cases of Elsberg syndrome, the average duration of urinary retention has been 26.9 days, and all patients improved (6, 10). The symptoms and clinical course of this case conformed well with this evidence.

Treatment of *A. cantonensis* infection is primarily supportive. Most patients with *A. cantonensis* eosinophilic meningitis require no specific treatment and recover completely within 3 to 6 weeks. Repeated lumbar punctures provide relief for patients with persistent headaches from increased intracranial pressure (1). In other cases, some clinicians have reported that steroid therapy helps to relieve these headaches as well as shortens the median time until the headaches dissipate (11). In this case, lumbar punctures and oral prednisolone provided relief for the patient's headaches and improved his general state along with the findings from the cerebrospinal fluid.

The major intermediate hosts of *A. cantonensis* are the African giant snail (*Achutina fulica*), the golden apple snail (*Ampullarium canaliculatus*) and humans infected by contact with intermediate hosts or carrier hosts (2). Although in the past infected causes were consuming the intermediate hosts

and carrier hosts, cases of unknown infected causes have been increasing in recent years (12), suggesting that infection tends to be through indirect contact with vegetables, hands and fingers, drinking water and raw vegetable juice (13), which have been contaminated with mollusk slime. The patient in this case was a cook, so we considered the infection route in this case to be from hands and fingers, the

indirect contact with vegetables. In addition, in most recent reports, the infection rate for previous host animals of *A. cantonensis* has obviously decreased, so it is suspected that their host animals have been changing (12). In summary, we described a case of eosinophilic meningoencephalitis with Elsberg syndrome.

---

## References

---

1. Lo Re V 3rd, Gluckman SJ. Eosinophilic meningitis. *Am J Med* **114**: 217-223, 2003.
2. Tsai HC, Liu YC, Kunin CM, et al. Eosinophilic meningitis caused by *Angiostrongylus cantonensis*: report of 17 cases. *Am J Med* **111**: 109-114, 2001.
3. Herbaut AG, Voordecker P, Monseu G, Germeau F. Benign transient urinary retention. *J Neurol Neurosurg Psychiatry* **50**: 354-355, 1987.
4. Kido M, Kawana T. Radiculomyelopathy due to genital herpes simplex virus infection (Elsberg syndrome). *Ryoikibetsu Shokogun Shirizu* **24 Pt 2**: 52-54, 1999 (in Japanese).
5. Zenda T, Soma R, Muramoto H, et al. Acute urinary retention as an unusual manifestation of aseptic meningitis. *Intern Med* **41**: 392-394, 2002.
6. Hamada E, Okamoto K, Okuda B, et al. Acute disseminated encephalomyelitis (ADEM) with Elsberg syndrome: clinical report of two cases. *Nippon Naika Gakkai Zasshi* **94**: 2379-2381, 2005 (in Japanese).
7. Sakakibara R, Uchiyama T, Liu Z, et al. Meningitis-retention syndrome. An unrecognized clinical condition. *J Neurol* **252**: 1495-1499, 2005.
8. Kuberski T. Eosinophils in cerebrospinal fluid: criteria for eosinophilic meningitis. *Hawaii Med J* **40**: 97-98, 1981.
9. Graber D, Hebert JC, Jaffar-Bandjee MC, Alessandri JL, Combes JC. Severe forms of eosinophilic meningitis in infants of Mayotte. Apropos of 3 cases. *Bull Soc Pathol Exot* **92**: 164-166, 1999 (In French, Abstract in English).
10. Hayashi R, Oohara S. Elsberg shokogun. *Annual Review Shinkei* **2004**: 127-132, 2004 (in Japanese).
11. Chotmongkol V, Sawanyawisuth K, Thavornpitak Y. Corticosteroid treatment of eosinophilic meningitis. *Clin Infect Dis* **31**: 660-662, 2000.
12. Asato R, Taira K, Nakamura M, Kudaka J, Itokazu K, Kawanaka M. Changing epidemiology of *Angiostrongyliasis cantonensis* in Okinawa prefecture, Japan. *Jpn J Infect Dis* **57**: 184-186, 2004.
13. Tsai HC, Lee SS, Huang CK, Yen CM, Chen ER, Liu YC. Outbreak of eosinophilic meningitis associated with drinking raw vegetable juice in southern Taiwan. *Am J Trop Med Hyg* **71**: 222-226, 2004.