琉球大学学術リポジトリ

# [症例報告]Meckel's Diverticulum in Children : Its Complications and Preoperative Diagnosis



| メタデータ | 言語: English<br>出版者: 琉球大学医学部<br>公開日: 2010-06-30<br>キーワード (Ja):<br>キーワード (En): Meckel's Diverticulum, Preoperative diagnosis, ^<99m>TC-pertechnetate scintigraphy<br>作成者: Hokama, Akira, Sho, Yoshiyuki, Hirayama, Kiyotake, Yamazato, Masahito, Kurihara, Kotaro, Oshiro, Takashi, Hokama, Tomiko<br>メールアドレス:<br>所属: |
|---|---|
| URL | http://hdl.handle.net/20.500.12000/0002015739 |

Ryukyu Med. J. 6 (1): 58～65, 1983.

# Meckel's Diverticulum in Children - Its Complications and Preoperative Diagnosis

Akira Hokama, Yoshiyuki Sho, Kiyotake Hirayama*
Masahito Yamazato, Kotaro Kurihara, Takashi Oshiro*
and Tomiko Hokama*

The First Department of Surgery School of Medicine, University of the Ryukyus.
* Department of Pediatrics School of Medicine, University of the Ryukyus.

Key words: Meckel's Diverticulum, Preoperative diagnosis, $^{99m}$TC-pertechnetate scintigraphy

## Introduction

The incidence of Meckel's diverticulum, a manifestation of the omphalomesenteric duct, is about 1.5 per cent of the general population, and male patients are twice as often affected as females[1]. Clinically it occurs infrequently. There have been many recent reports on Meckel's diverticulum diagnosed preoperatively using abdominal scanning with $^{99m}$Tc-pertechnetate.[2)3)4)] Radiologic or angiographic examination is sometimes useful in diagnosis.

We recently managed four cases of Meckel's diverticulum, and one was diagnosed preoperatively. In this paper, our three pediatric cases are presented, and complications and problems in preoperative diagnosis are discussed.

## Case Reports

Case 1, K.Y., a 9-year-old boy was admitted to the Hospital of the University of Ryukyus with abdominal pain and bloody stools. He had been suffering from repeated attacks of abdominal pain since he was six. He underwent appendectomy at the age of seven in another hospital, but no inflammatory changes of the resected vermiformis appendix was found. Following the appendectomy attacks of abdominal pain with bloody stools have repeated as before appendectomy. On admission, his conjunctivae were markedly anemic. The abdomen was flat and soft with no tenderness. Blood count showed a hemoglobin of 7.2 g, and hematocrit of 21.7%, a red blood cell count of $266\times 10^4$ and a white blood cell count of 4200 with a normal differential. Abdominal scanning with $^{99m}$Tc-pertechnetate was carried out demonstrating an abnormal area of uptake in the midabdomen (Fig. 1). A diagnosis of Meckel's diverticulum was then made. At the operation a Meckel's diverticulum was identified 55 cm from the ileocecal valve, and was $5.0\times 2.5\times 2.0$ cm in size (Fig.2).
Partial resection of the ileum including the Meckel's diverticulum was performed (Fig. 3). The mucosa of the diverticulum was apparently different from the adjacent ileal mucosa.

Microscopic examination revealed ectopic gastric mucosa in the diverticulum and a peptic ulcer was found at the boundary between the normal and ectopic mucosa. Postoperative recovery was uneventful, and he was discharged from the hospital at fourteenth postoperative day.

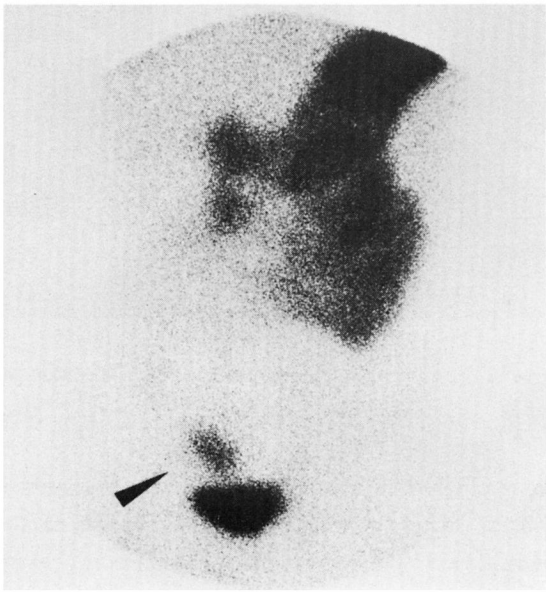

Fig.1 Preoperative scan on case 1. 30 minutes after injection of $^{99m}$Tc-pertechnetate (5 mCi). The arrow shows abnormal accumulation of radiopertechnetate above the urinary bladder.

Fig.2 Operative view of the Meckel's diverticulum in case 1.

Fig.3 Opened surgical specimen showing ulcer at the boundery of mucosa of the diverticulum and that of ileum in case 1.

Case 2, J.T., a 14-year-old junior high school girl was referred to our service from a private clinic. She had been suffering from periodic symptoms of abdominal distention and slight fever since she was five. She underwent appendectomy at the age of 10. Twelve months later she was admitted to another hospital with suspicion of volvulus receiving a conservative treatment. Subsequently she has however had attacks of abdominal pain repeatedly.

Physical examination revealed an alert girl in no acute distress. The temperature, pulse rate, and respirations were normal. Abdomen was flat and soft. Liver, spleen and kidneys were not palpable. Only slight tenderness in the abdomen just right to the umbilicus was noted. Examinations of blood and urine were within normal limits. Alimentary examination of the gastrointestinal tract showed no evidence of pathologic changes, but dilated loops of the ileum in the pelvis. A preoperative diagnosis of segmental dilatation of the ileum was made (Fig.4).

At the operation, a remarkable dilatation of the ileum, 10 cm in diameter, was noted 70 cm oral to the ileocecal valve. A band ran from the mesentery to the antimesenteric site of this dilatation. The affected segment, 20 cm in length, was resected. On histologic examination, the specimen contained heterotopic pancreatic tissue but no gastric mucosa (Fig.5). The band was occluded blood vessels which was consistent with a mesodiverticular vascular band. The symtoms of incomplete intestinal obstruction were presumably resulted from strangulation around this band. The postperative course was uneventful and she was discharged from the hospital at the nineth postoperative day.

Case 3, M.Y., a 42-day-old boy with the body weight of 3150 gm. was admitted to the hospital with the symptoms of increasing abdominal distension and vomiting for several days duration. On admission he was in acute distress with tachypnea. The abdomen was markedly

distended. The plain roentgenogram of the abdomen showed dilated loops of bowel throughout the entire abdomen. Laparotomy was carried out with a preoperative diagnosis of illdefined intestinal obstruction. An ileoileal intussusception was found 40 cm from the ileocecal valve with remarkable dilatation of the small intestine requring resection of 10 cm long segment of the ileum. The surgical specimen revealed an inverted diverticulum which acted as the leading point of the ileoileal intussusception (Fig.6)

Although his postoperative course was stormy, he fully recovered and was discharged from the hospital in good condition.

Fig.4 Barium meal study of case 2 showed marked dilatation of ileum.

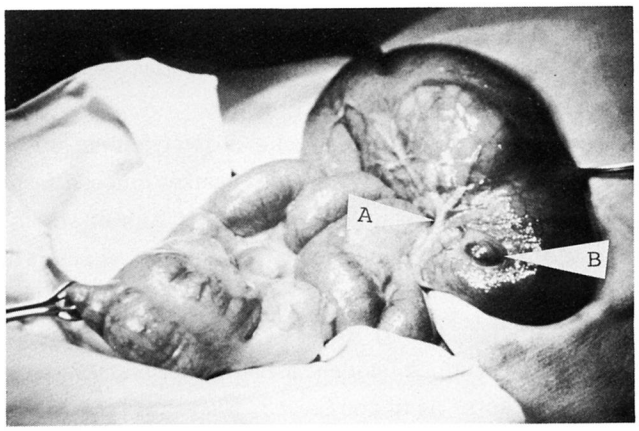


Fig.5 Operative view of case 2 : Giant Meckel's diverticulum ; Note the mesodiverticular band (arrow A ) and ectopic pancreas ( arrow B ).

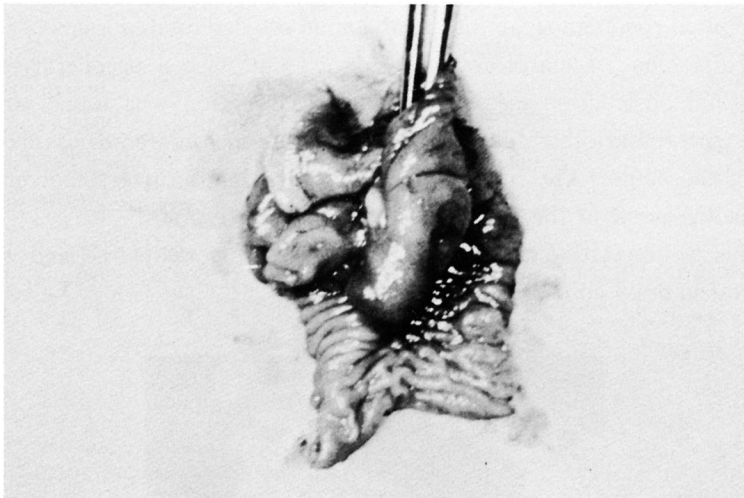

Fig.6 Inverted Meckel's diverticulum which produced ileo-ileal intussusception in case 3.

## Discussion

Although Meckel's diverticulum is encountered infrequently clinically, it may rapidly give rise to life threatening complications. Significantly, half of the patients with symptomatic Meckel's diverticulum are under the age of two.

Major complications of Meckel's diverticulum are hemorrhage, intestinal obstruction and inflammation. Rutherford and Akers[6] reviewed 148 pediatric cases of Meckel's diverticulum, of which 106 incidental findings at laparotomy and the rest were at autopsy. 80 cases caused clinical complications : bleeding in 43 cases, obstruction in 26, inflammation in 8, and perforation in 3. Benson[7] reported 115 cases in which bleeding occurred in 40.9%, obstruction in 32.2%, and diverticulitis in 20.8%. Rutherford and Akers reported that the diverticulum was found to contain heterotopic tissue in 57% of the symptomatic cases, in contrast to only 6% of asymptomatic cases. Of cases with heterotopic tissue, gastric mucosa was found in 78.1% of cases, pancreatic tissue in 15.4%, colon mucosa in 3.1% and jejunal or duodenal mucosa in 1.5%. In our cases, Case 1 had ectopic gastric mucosa with ulceration and Case 2 had pancreatic tissue.

Bleeding is a common manifestation of Meckel's diverticulum due to peptic ulceration produced by secretion of acid-pepsin by heterotopic gastric mucosa in the diverticulum.

Intestinal obstruction also occurs in one third of symptomatic Meckel's diverticuli. Rutherford and Akers reported 26 intestinal obstruction out of 80 symptomatic cases, including intussusception in 7, volvulus in 7, entrapment of intestine by the mesodiverticular band in 6, inflammatory obstruction in 4, and Littre's hernia in 2. An inverted Meckel's diverticulum in the ileal lumen may produce ileoileal intussusception, and occur in as high as 50 % of intestinal obstruction in infants[1] as in our Case 3. Seagram[5] stated that the postoperative morbidity in cases with intestinal obstruction associated with Meckel's diverticulum is higher than those in cases with bleeding.

Mesodiverticular bands may also cause intestinal obstruction. Our Case 2 had a band which ran from the base of the mesentery to the distal portion of the dilated ileum. Her chronic symptoms of incomplete intestinal obstruction might be produced by strangulation of the small intestine around the congenital band. Seagram also reported a similar case.

Acute suppurative diverticulitis may occur when the ostium is obstructed[5] and hardly distinguishable from acute suppurative appendicitis. Case 1 and Case 2 had undergone appendectomy in the past, but their symptoms were not typical of appendicitis. True suppurative Meckel's diverticulitis is quite rare in children. Rutherford and Akers[6] had only 4 cases in their 25 year experience. Perforation of the Meckel's diverticulum rarely occurs secondary to peptic ulceration, inflammation, or ingested foreign body. On the other hand, preoperative diagnosis of Meckel's diverticulum still remains difficult. Yamaguchi[8] reviewed 600 cases of Meckel's diverticulum, and preoperative diagnosis was possible in only 34 cases (5.7%). 5 cases were identified by fluoroscopic examination and 15 were by $^{99m}$Tc pertechnetate, two of them also underwent angiography.

Since Jewett[2] reported the usefulness of $^{99m}$ Tc-pertechnetate in visualization of Meckel's diverticulum, many cases have been reported identifying it preoperatively[3)9)10)11], including more than 30 cases in Japanese literature[4)12]. Our Case 1 was also possible to identify preoperatively by this technique. $^{99m}$ Tc-pertechnetate has an affinity for gastric parietal cells. Although this technique is valuable, there are false positive or false negative studies. False positive scans have been reported in patients with other abnormalities, such as intussusception, hydronephrosis or arteriovenous malformations[3]. We have experienced a case of a false positive scan, which proved to be an intussusception due to a jejunal polyp at the operation.

Fletcher[10] studied 41 cases with pertechnetate scanning. Ten cases had positive scans while 31 had negative scans. Ten positive scans were found to be Meckel's diverticulum in 5, duplication cyst with ectopic gastric mucosa in one and false positive in 4. Out of 31 negative scans, 3 false negative were disclosed including 2 of Meckel's diverticulum and one of duplication cyst with ectopic gastric mucosa by laparotomy. However, in his series another observer suggested that 8 scans were positive and 33 were negative - i.e., no false positive scans and only one false negative. This suggests that the interpretation of scintigrams may be difficult, and accuracy should be improved by experiences. In diagnosis of bleeding Meckel's diverticulum, although selective superior mesenteric arteriogram has been used demonstrating extravasation of contrast material or a collection of tortuous vessels in the ileal branches[13)14], simple examination technique should be utilized in infants. Selective angiography in infants is difficult and/or troublesome, and besides children should be kept away from excessive irradiation exposure.

Therefore, abdominal scanning with $^{99m}$ Tc-pertechnetate should be done routinely in cases with the suspicion of Meckel's diverticulum, keeping the possibility of scan misinterpretation in mind.

(Summary of this paper was presented at the 18th Congress of the Japanese Society of Pediatric Surgeons at Sapporo, 1981. )

**Summary**

Four cases of Meckel's diverticulum were experienced in our clinic. Three of them were pediatric patients. In this paper preoperative diagnosis and the complications were discussed.

Case 1 : A 9-yr-old boy complained of attacks of abdominal pain and tarry stool. Before surgery Meckel's diverticulum was diagnosed by $^{99m}$Tc-pertechnetate. In histological section, the ectopic gastric mucosa was found in the resected diverticulum.

Case 2 : A 14-yr-old girl presented with periodic abdominal distension and fever. At surgery a giant Meckel's diverticulum with mesodiverticular band was seen in the ileum. This band was considered as a cause of incomplete intestinal obstruction. The resected diverticulum showed the ectopic pancreatic tissue.

Case 3 : A 6-wk-male baby was brought to our hospital with abdominal distension and vomiting. At surgery intussusception of the ileum was found. Meckel's diverticulum acted as the leading point of this intussusception.

Based on our clinical experience, in preoperative diagnosis of Meckel's diverticulum $^{99m}$Tc-pertechnetate is usefull and harmless to the patients. The postoperative courses of these patients were uneventful.

**Acknowledgment**

We thank Dr. J.P. Murphy, JR. of US Naval Regional Medical Center, Okinawa, for editing the manuscript in English.

**References**

1) Ravitch, M.M. : Pediatric surgery, 3rd ed., pp955–960, Year Book Medical Publishers, INC., Chicago. London, 1979.

2) Jewett, T.C., Duszynski, D.O., and Allen, J.E. : The visualization of Meckel's diverticulum with $^{99m}$Tc-pertechnetate, Surgery 68: 567-570, 1970.

3) Berquist, T.H.: Specificity of $^{99m}$Tc-pertechnetate in scintigraphic diagnosis of Meckel's diverticulum : Review of 100 cases, J. Nucl. Med. 17: 465-469, 1976.

4) Nishimura, S. Ikeda, K., Nagasaki, A., and Oshiumi, Y. : Two cases of Meckel's diverticulum diagnosed by $^{99m}$Tc-pertechnetate scintigraphy, Jap. J. Pediat. Surg. 13: 533-539, 1981.

5) Seagram, C.G.F., Rough, R.E., Stephens, C.A. and Wentworth, P. : Meckel's diverticulum : A 10 year review of 218 cases, Canad. J. Surg. 11: 369-373, 1968.

6) Rutherford, R.B. and Akers, D.R. : Meckel's diverticulum : A review of 148 pediatric patients, with special reference to mesodiverticular bands, Surgery 59: 618-626, 1966.

7) Benson, C.D., and Linkner, L.M. : The surgical complications of Meckel's diverticulum in infants and children, Arch. Surg. 73: 393, 1978.

8) Yamaguchi, Y., Takeuchi, S., and Awazu, S. : Meckel's diverticulum (investigation of 600 patients in Japanese litereture), Amer. J. Surg. 136: 247-249, 1978.

9) Jaros, R., Schussheim, A. and Levy, L.M. : Preoperative diagnosis of bleeding Meckel's diverticulum utilizing 99m-technetium pertechnetate scinti-imaging, J. Pediatr. 82: 45-49, 1973.

10) Fletcher, P. and Andrews, J.T. : Abdominal scanning for bleeding Meckel's diverticulum using $^{99m}$Tc-pertechnetate, Aust. Paediatr. J. 14: 244-247, 1978.

11) Rosenthall, L., Henry, J.N., Murphy, D.A. and Freeman, L.M. : Radiopertechnetate imaging of the Meckel's diverticulum, Radiology 105: 371-373, 1972.

12) Fukui, Y., Okada, T., Kitazume, H., Imura, K., Maeda, H., Tamura, K., Nakao, K., and Kawashima, Y. : Two cases of Meckel's diverticulum diagnosed before operation, Surgical Therapy 47: 733-737, 1982.

13) Faris, J.C. and Whitley, J.E. : Angiographic demonstration of Meckel's diverticulum, Radiology 108: 285-286, 1973.

14) Takeda, I., Nakano, S., Kitamura, K., : A bleeding Meckel's diverticulum diagnosed by arteriography, Gastroenterol. Jpn. 12: 76-79, 1977.