琉球大学学術リポジトリ

[症例報告]Hypomelanosis of Ito Syndrome Associated with Chromosomal Aberration

メタデータ	言語: English 出版者: 琉球大学医学部 公開日: 2010-06-30 キーワード (Ja): キーワード (En): Hypomelanosis of Ito syndrome, Hypopigmentation, neurocutaneous syndrome 作成者: Hokama, Tomiko, Naritomi, Kenji, Hirayama, Kiyotake メールアドレス: 所属:
URL	http://hdl.handle.net/20.500.12000/0002015769

Ryukyu Med. J., 8(4): 170~174, 1985.

Hypomelanosis of Ito Syndrome Associated with Chromosomal Aberration

Tomiko Hokama, Kenji Naritomi* and Kiyotake Hirayama*

Department of Maternal & Child Health, School of Health Sciences,
Faculty of Medicine, University of the Ryukyus.
* Department of Pediatrics, School of Medicine,
Faculty of Medicine, University of the Ryukyus.

Key words: Hypomelanosis of Ito syndrome, Hypopigmentation, neurocutaneous syndrome

Abstract

Hypomelanosis of Ito syndrome is a rare neurocutaneous syndrome characterized by linear hypopigmentation associated with a variety of anomalies of central nervous system, the eye and musculoskeletal structures. A case of 5-year-old girl with typical hypomelanosis of Ito syndrome is reported in this paper. This patient was associated with chromosomal abberation which had not been mentioned in previous reports.

Introduction

Hypomelanosis of Ito syndrome was initially described by Ito[1] in 1952 and more than 20 cases of affected indivividuals of various ethnic origins had been reported until 1972[2]. Hypomelanosis of Ito syndrome is a distinct entity characterized by linear Hypopigmentations and includes a variety of anomalies of central nervous system, the eye and musculoskeletal structures. Etiology has been unknown but some familial case reports[3),4)] suggest autosomal dominant inheritance.

The patient described in this paper was a 5-year-old girl who had linear and mottled areas of Hypopigmentation, mental retardation, strabismus and asymmetry in leg length. Chromosomal analysis was 46, XX／47,XX, + mar.

Case Report

A 5-year-old girl was referred to our outpatient clinic in February 1985 because of preoperative examination for cleft palate. She was delivered normally at full term, being the second of three siblings. There is no consanguinity in the family. The mother was 27-year-old at delivery, was quite healthy and had not taken any drugs known to affect fetal development. The birth weight was 2900 grams. At neonatal period tube feeding was necessary because of poor sucking during first two days.

At birth it was noted that she had linear and mottled area of hypopigmented macules of bizarre irregularity on the trunk and extremities. Hypopigmentation had improved gradually after birth. At age 1 year, she suffered from aseptic meningitis and admitted to other hospital for two weeks. Submucosal cleft palate was detected at age 5 years because of nasal voice.

Her mental and moter development were retarded. Head control developed at 6 months, she could not walk until 2 years and 3 months, and spoke monosyllabus words at age 3 years.

On physical examination height was 103.5cm (−1.0 SD) and weight was 15.4kg (−1.3 SD). Facial expression was slightly idiotic. She had strabismus. Cardiac sounds were normal and lungs were clear. The liver and spleen were not palpable. Asymmetry in leg length was seen, right leg was 51cm and left leg was 49 cm with mild scoliosis. The skin showed linear and mottled macular hypopigmfnted areas on the posterior aspects of the trunk and all extremities (fig. 1). Minor anomalies such as left polythelia, sacral dimple and bilateral short fingers were also seen.

Complete blood count and urinalysis were normal. Serologic test for syphilis was negative. Roentgenogram of skull was normal and roentgenogram of chest showed mild scoliosis. An elrctroencephlogram was within normal limit. Lymphocyte karyotype with G-banding showed 46, XX/47, XX,+mar (fig. 2). Lymphocyte karyotype of her parents were normal.

Her developmental quotient was 53.

Discussion

Hypomelanosis of Ito syndrome was reported by Ito[1] (1952) as variant of nevus depigmentosus systematicus bilateralis. Schwartz et al[2] (1977) reviewed extensively eight cases of affected individuals. The condition appears negative image of incontinentia pigmenti. Hypopigmented, asymmetric, bizarre whorls and streaks occur bilaterally. The condition may appear at or shortly after birth, or later in childhood. Associated noncutaneous abnormalities are seen in central nervous system, the eye and musculoskeletal structures. Several features of hypomelanosis of Ito syndrome differentiate it from an incontinentia pigmenti, systematized depigmented nevus and partial albinism as follows[5]:

1) Frequent association of noncutaneous abnormalities such as central nervous system, the eye and musculoskeletal structures.
2) Onest variability of skin lesions, from at birth to childhood.
3) Variability of the lesions, an initial tendency to progression and subsequent improvement but no erythematous and bullous phase in incontinentia pigmenti.

Grosshans et al[3] (1971) and Rubin[4] (1972) reported the familial case of hypomelanosis of Ito syndrome and these pedigrees suggest an autosomal dominant inheritance. A genetic or enzymatic defect of the neuroectodermal anlage present during the critical developmental stage may affect all organs derived from the neural crest, probablly due to a biochemical injury in the first or second trimester of pregnancy.

As to chromosomal analysis Jelinek et al[5] (1973), Happle et al[6] (1976) and Nordlund et

al[7] (1977) reported normal male and female karyotype. In our case she had typical cutaneous lesion from neonatal period and later slightly improved. She had also mental retardation, strabismus, cleft palate and asymmetry of leg length with scoliosis. This is a first case report of hypomelanosis of Ito syndrome assosiated with chromosomal abberation. It seems necessary to discuss the relationship between them in future case reports.

It is suggested that cutaneous pigmentary abnormalities especially if present at birth, might be a manifestation of a more generalized defect of all neuroectodermal derivatives. Hypomelanosis of Ito syndrome is one of neurocutaneous syndromes which pediatrician should be aware of.

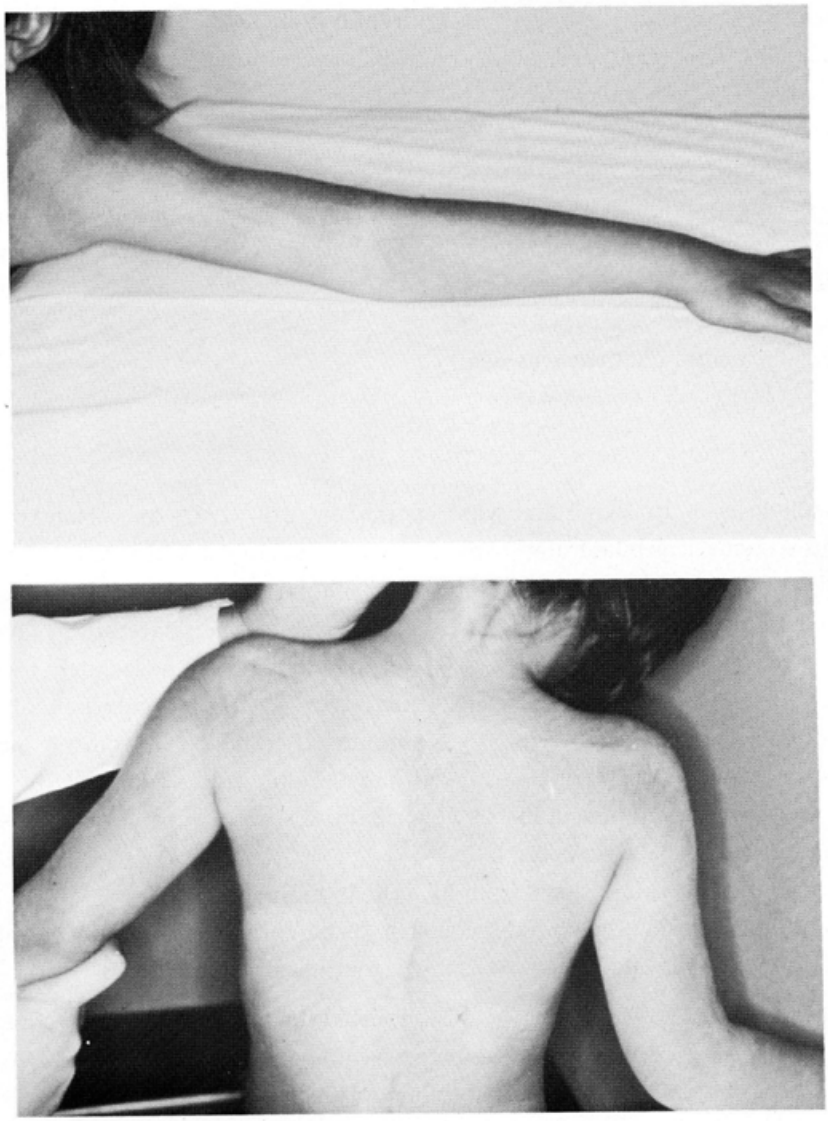

Fig. 1 Hypomelanosis on patient's left arm and back.

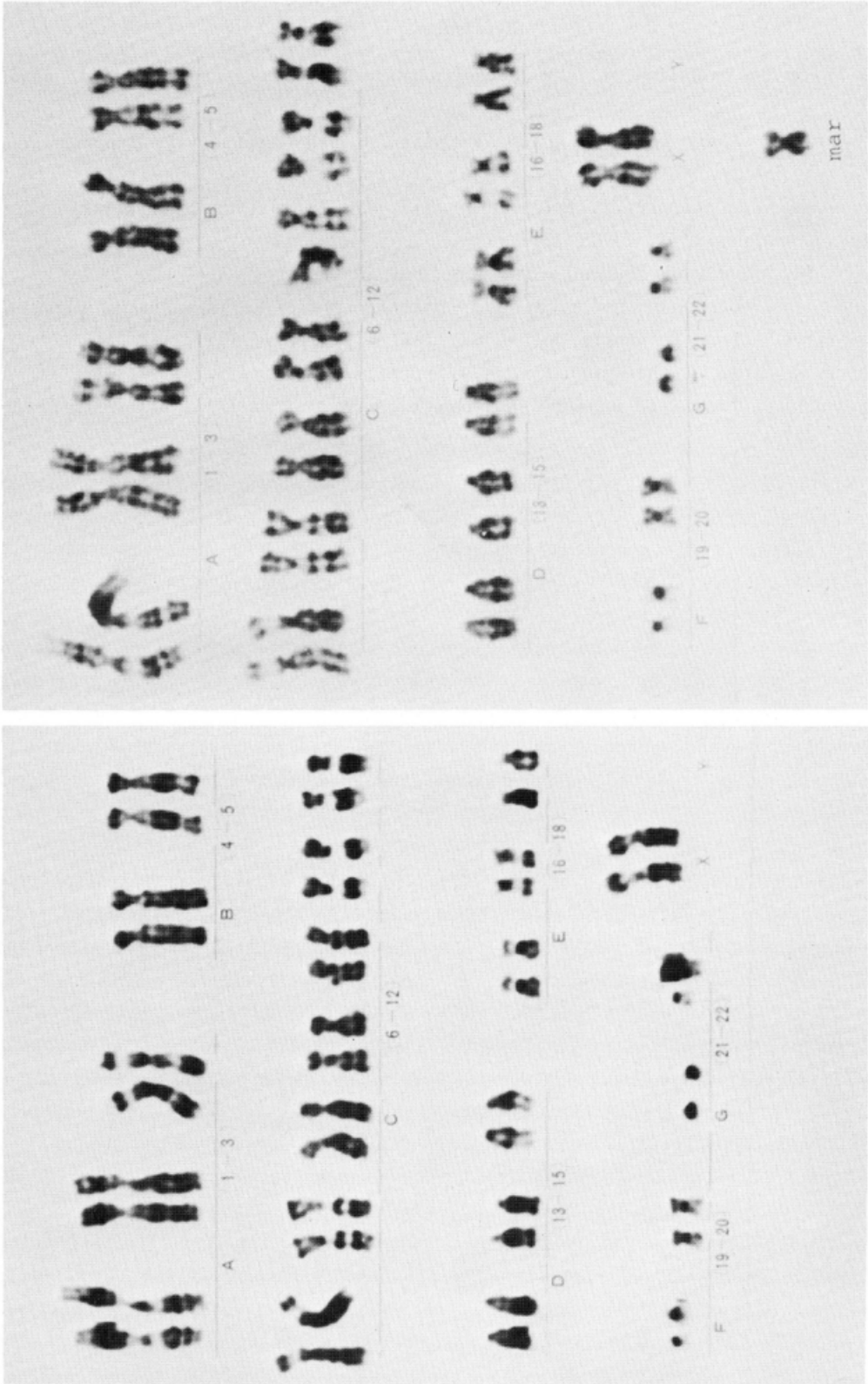

Fig. 2 Chromosome karyotype of the patient. 46,XX/47,XX +mar.

References

1) Ito, M.: Studies on melanin XI. Incontinentia pigmenti achromians, Tohoku J. Med., 55:57, 1952.

2) Schwartz, E., Esterly, N.B., Fretzin, D.F., Perganont, E. and Rosenfeld, I.H.: Hypomelanosis of Ito, J. pediatr., 90:236, 1977.

3) Grosshans, E.M., Staemner, P., Bercolnd, H. and Stoll, C.: Incontinentia pigmenti achromians (Ito), Dermatologica, 142:65−78, 1971.

4) Rubin, M.: Incontinentia pigmenti achromians, Arch. Dermatol., 105:424−425, 1972.

5) Jelinek, J.F., Bart, R.S. and Schiff, G.M.: Hypomelanosis of Ito "Incontinentia pigmenti achromians", Arch. Dermatol., 107:596−601, 1973.

6) Happle, R., Krenz, J. und Pfiffen, R.: Das Ito Syndrom, Hautartz, 27:286−290, 1976.

7) Nordlund, J.J., Klaus, S.N. and Gino, J.: Hypomelanosis of Ito, Acta. Derm. Venereol., 57:261−264, 1977.