琉球大学学術リポジトリ

[症例報告]Total aortic replacement for aortic dissection occurring in a patient with Mar fan syndrome

メタデータ	言語: English 出版者: 琉球医学会 公開日: 2010-07-02 キーワード (Ja): キーワード (En): aortic dissection, Mar fan syndrome, aortic replacement 作成者: Koja, Kageharu, Kuniyoshi, Yukio, Iha, Kiyoshi, Akasaki, Mitsuru, Miyagi, Kazufumi, Shimoji, Mitsuyoshi, Kusaba, Akira メールアドレス: 所属:
URL	http://hdl.handle.net/20.500.12000/0002016004

Total aortic replacement for aortic dissection occurring in a patient with Marfan syndrome

Kageharu Koja, Yukio Kuniyoshi, Kiyoshi Iha, Mitsuru Akasaki
Kazufumi Miyagi, Mitsuyoshi Shimoji and Akira Kusaba

Second Department of Surgery, Faculty of Medicine, University of the Ryukyus

(Received on March 11, 1997, accepted on April 22, 1997)

ABSTRACT

Total aortic replacement from valve to bifurcation was performed in a patient with Marfan syndrome in a two stage operation. The patient had a DeBakey type II aortic dissection with grade 3/4 aortic regurgitation and type III dissection with diffuse enlargement of false lumen. At the first operation, cardiopulmonary bypass, profound hypothermia, selective cerebral perfusion and circulatory arrest were employed while the aortic valve, ascending, aortic arch and proximal segment of descending thoracic aorta were replaced. At the second operation, the remaining descending thoracic and abdominal aortic segment were replaced, using femoro-femoral bypass. The patient has remained well 47 months after the second operation. To our knowlegde, this is the first successful case of total aortic replacement from valve to bifurcation in Japan. *Ryukyu Med. J., 17(1)61~64, 1997*

Key words: aortic dissection, Marfan syndrome, aortic replacement

INTRODUCTION

Chronic aortic regurgitation and aortic root dissection and rupture are the primary cause of the reduced life expectancy of patients with Marfan syndrome[1]. Prompt diagnosis and surgical repair should allow increased survival rate among patients with this hereditary disorder of connective tissue. A few reports of aortic surgery have recently switched from limited to extended graft replacement in the patients with Marfan syndrome for good late outcome[2-4]. However, the selection of the patient for total aortic replacement has been controversial, considering its operative mortality and morbidity. We present herein a patient with Marfan syndrome who underwent successful two stage total aortic replacement. The presentation and management of a patient with Marfan syndrome who had extensive aortic dissection is discussed.

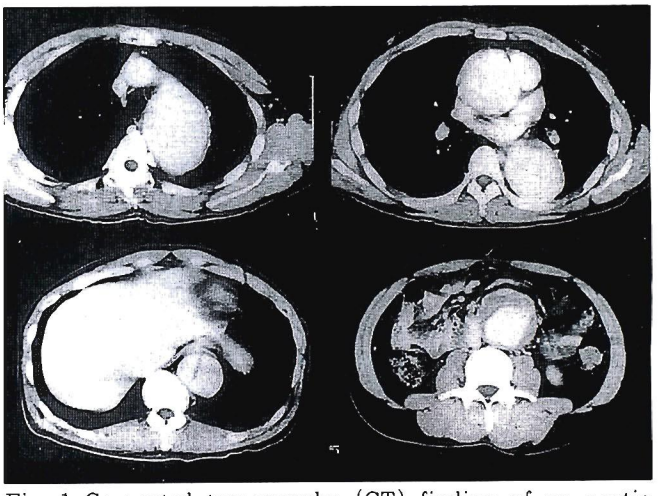

Fig. 1 Computed tomography (CT) finding of an aortic aneurysm. Diffuse aneurysmal dilatation with dissection is seen from the ascending to abdominal aorta.

CASE REPORT

A 34-year old man with severe pain in the chest and low back was diagnosed as having dissecting aortic aneurysm in the emergency center and transferred to our hospital. Three years ago, he also suffered from chest pain and dyspnea, and recovered uneventfully. He was 180 cm in height and had typical Marfan habit (pes planus, thoracic dorsis, pectus deformity, arachnodactyly and ectopia lentis). Nevertheless, the diagnosis of Marfan syndrome had not been made previously. There was a grade 3/6 regurgitation murmur in aortic area and electrocardiogram showed left ventricular hypertrophy with a strain pattern. Enlargement of aortic arch was observed in the chest X-ray. Computed tomography (CT) scanning revealed massive aneurysmal dilatation and dissection of almost entire aorta (Fig. 1). Aortography confirmed DeBakey type II aortic dissection with grade

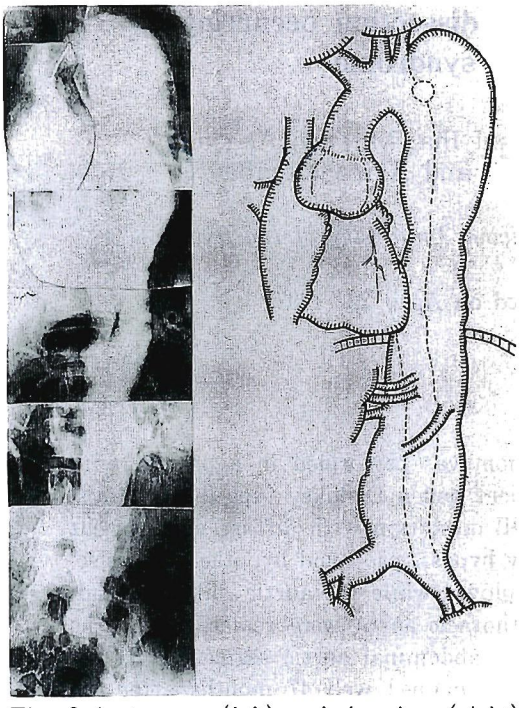

Fig. 2 Aortogram (left) and drawing (right) made before operation showing DeBakey type II aortic dissection with grade III aortic regurgitation and type III dissection with massive dilatation of false lumen.

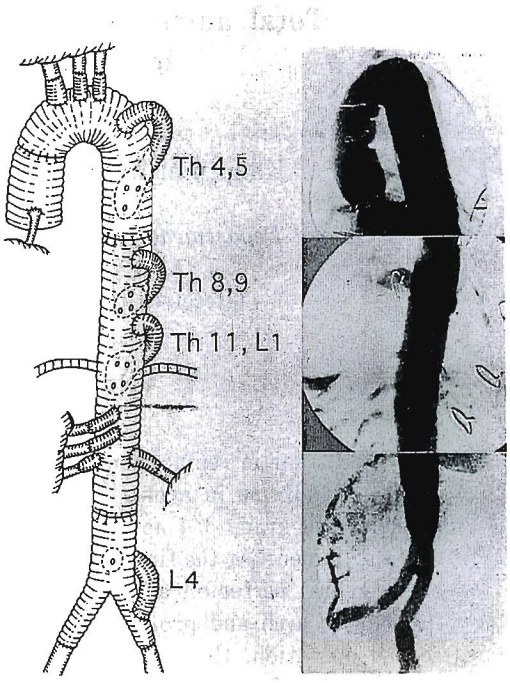

Fig. 4 Drawing (left) and aortogram (right) made after the second operation showing good function of the totally replaced aorta with preservation of intercostal, visceral, and lumbar arteries.

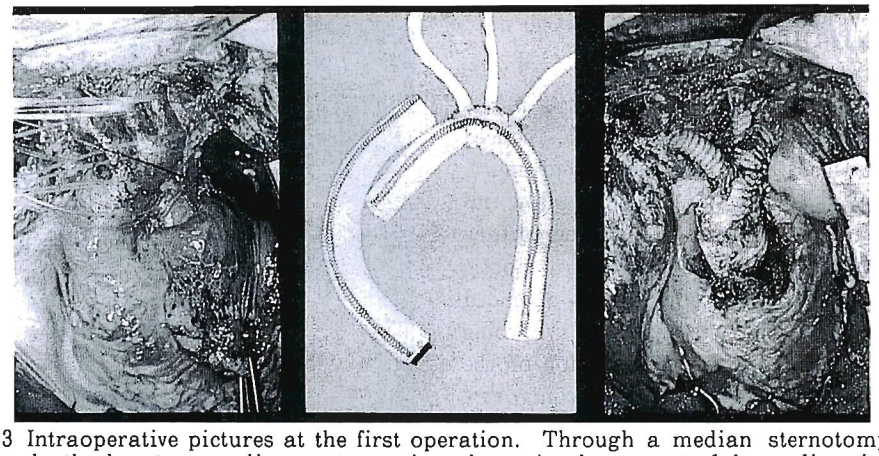

Fig. 3 Intraoperative pictures at the first operation. Through a median sternotomy approach, the heart, ascending aorta, arch and proximal segment of descending thoracic aorta is exposed (left). Valved conduit for aortic root replacement and three-limbed arch graft are shown (center). Completion of first stage aortic replacement from valve to proximal segment of descending thoracic aorta with two composite grafts (right).

III aortic regurgitation and type III dissection with diffuse dilatation of the false lumen (Fig. 2). Based on his preoperative findings and progressive nature of this disorder in patients with Marfan syndrome, total aortic replacement was performed in two stages.

At the first operation on October 8, 1992, the heart, ascending aorta, arch and proximal segment of descending thoracic aorta were exposed through a median sternotomy (Fig. 3). Employing cardiopulmonary bypass, profound hypothermia (18℃, rectal), selective cerebral perfusion and circulatory arrest, the aortic root was replaced with a composite valve graft and the coronary arteries reattached by button technique[5]. Simultaneously, the aortic arch and proximal segment of the descending thoracic aorta were replaced with a three-limbed arch graft (Fig. 3, Fig. 4). Two pairs of intercostal artery (Th4, 5) were reimplanted during this procedure.

After complete recovery, the second operation was

performed on March 17, 1993. Through the spiral opening approach, the remaining thoracoabdominal aorta (from the distal segment of descending thoracic aorta to the aortic bifurcation) were completely exposed. Using partial femoro-femoral bypass and multi-aortic clamping technique[6] the aortic graft replacement was performed with reimplantation of three pairs of intercostal and two pairs of lumbar arteries and reattachment of celiac, superior mesentric and renal arteries (Fig. 4).

The patient had an uneventful postoperative course without any signs of paraplegia and postoperative aortogram showed good function of the reconstructed aorta from valve to bifurcation (Fig. 4). The patient remains well in good health 47 months after the total aortic replacement.

DISCUSSION

The natural history of the Marfan syndrome has been well described by Murdoch *et al*[7]. In their series of 257 patients, the mean age of death was 32 years. The causes of death were mostly the result of cardiac or aortic factors, with aortic root complication and aortic dissection or rupture. Therefore, prolongation of lifespan in patients with Marfan syndrome is dependent upon prevention and management of these cardiovascular manifestations.

Surgical treatment should be related to the anatomic diagnosis and must be a well established procedure devised for the abnormalities occurring in the various segments of the affected aorta and the left sided heart valves. Regarding the multiple cardiovascular manifestations of Marfan syndrome, Svensson *et al*[8] reported 280 aortic operations in 151 patients and Coselli et al[4] also reported 117 operations in 59 patients in multistages. Many other studies also revealed that new developments involving additional aneurysms in the remaining aortic segments, necessitated extended aortic replacement in multi-stage operation in patients with Marfan syndrome[2,5,9,10]. In view of it's progressive nature and preoperative findings, we performed total aortic replacement including a short segment of nondilated ascending aorta in this patient.

Controversy exist regarding the surgical management of simultaneous or stages operation during total aortic replacement. Massino *et al*[3] experienced 21 patients requiring simultaneous total aortic replacement from valve to bifurcation and reported a 14.2% operative mortality and 72% with a 5-year survival rate. But early postoperative complications in their 21 patients included renal failure in 2 patients, central neurologic disturbances in one and neurologic disturbances of lower extremities in 3 patients. Crawford *et al*[2] analyzed their 53 patients requiring total aortic replacement in multi-stage operation and reported 8 % early deaths and 21% late deaths. Although early and late deaths of Crawford procedure were low, the early postoperative outcome included renal failure in 2 patients, central neurologic deficit in 3 and neurologic disturbances of lower extremities in 10 patients. They noted that when ascending and aortic arch were replaced first because of size and symptoms it could minimize the cardiac complications of subsequent operations. Although simultaneous aortic replacement is the ideal treatment for disease involving the whole aorta, most cardiac surgeons prefer the multi-stage operation considering the complicated procedure and the high operative risk of the one stage operation[2,4,8-10]. We therefore selected the two-stage operation in view of it's low mortality and morbidity rate in our patients.

As an adjunct to extended aortic aneurysm surgery, deep hypothermia with circulatory arrest has been mostly used as in the Massino and Crawford groups. However, many disadvantages of this procedure for brain protection have been reported[8,11,12]. A selective cerebral perfusion technique[13] was performed on our patient during first stage operation for cerebral protection and consequently he did not develop any neurologic disturbances.

Paraplegia, probably caused by a temporary reduction of the perfusion pressure to the spinal cord during or after the thoracoabdominal aortic operation, is still feared with catastrophic complications[14-16]. It remains an unsolved source of severe morbidity. We reported that routine reimplantation of many large intercostal and lumbar arteries under the multi-aortic clamping technique could decrease the incidence of paraplegia during the thoracoabdominal aortic replacement using femoro-femoral bypass[6]. In this patient, five pairs of intercostal and two pairs of lumbar arteries were reimplanted during the second operation. The late outcome of the patient has been well without any signs of paraplegia.

While reports of total aortic replacement are few[9,10,17], a total aortic replacement including the aortic valve has not been previously reported in Japan. This case report emphasizes that patients with Marfan syndrome who have diffuse aortic involvement may be best treated by extensive aortic replacement.

REFERENCES

1) McDonald G.R., Schaff H.V., Pyeritz R.E., McKusick V.A. and Gott, V.L.: Surgical management of patients with the Marfan syndrome and dila tation of the ascending aorta. J. Thorac. Cardiovasc. Surg. 81: 180-186, 1981.

2) Crawford E.S., Coselli J.S., Svensson L.G., Safi H.J. and Hess K.R.: Diffuse aneurysmal disease (Chronic aortic dissection, Marfan, and Mega aorta syndromes) and multiple aneurysm. Ann. Surg. 211: 521-537, 1990.

3) Massino C.G., Presenti L.F., Favi P.P., Crisci C. and Guadron, E.A.C.: Simultaneous total aortic replacement from valve to bifurcation: Experience with 21 cases. Ann. Thorac. Surg. 56: 1110-1116, 1993.
4) Coselli J.S. and Buket S.: Marfan syndrome: The variability of operative management: Cardiovascular aspect of Marfan syndrome. (Hetzer, R., Gehle, R., Ennker, J. ed) pp91-100, Springer, Berlin, 1995.
5) Kouchoukos N.T., Marshall W.G., and Wedige-Stecher, T.A.: Eleven-year experience with composite graft replacement of ascending aorta and aortic valve. J. Thorac. Cardiovasc. Surg. 92: 691-705, 1986.
6) Koja K., Kuniyoshi Y., Iha K., Akasaki M., Kugai T., Kina M. and Kusaba A.: One stage aortic graft replacement for extensive thoracoabdominal aortic aneurysm. Jpn. J. Cardiovasc. Surg. 19: 282-284, 1989 (in Japanese).
7) Murdoch J.L., Warker B.A., Halpern B.A., Kuzma J.W. and Mckusick V.A.: Life expectancy and causes of death in the Marfan syndrome. N. Engl. J. Med. 286: 804-808, 1972.
8) Svensson L.G., Crawford E.S., Hess K.R., Coselli J.S., Raskin S., Shenaq S.A. and Safi H.J.: Deep hypothermia with circulatory arrest. Determinants of stroke and early mortality in 656 patients. J. Thorac. Cardiovasc. Surg. 106: 19-31, 1993.
9) Miura M., Mohri H., Tabayashi K., Suzuki Y., Ito, T., and Horiuchi T.: A case of total aortic replacement in a patient with Marfan syndrome. J. Jpn. Thorac. Surg. 39: 2223-2228, 1991 (in Japanese).
10) Sekine S., Abe T., Kuribayashi R., Aida H., Seki K. and Shibata Y.: Total aortic replacement in a patient with extensive thoracoabdominal aortic aneurysm. J. Jpn. Thorac. Surg. 42: 247-252, 1994 (in Japanese).
11) Hickey P.R. and Andersen N.P.: Deep hypothermic circulatory arrest: a review of pathophysiology and clinical experience as a basis for anesthetic management. J. Cardiovasc. Anesth. 1: 137-155, 1987.
12) Filgueiras C.L., Ryner L., Ye J., Yang L., Ede M., Sun J., Kozlowski P., Summers R., Saunders J.K., Salerno T.A. and Deslauriers R.,: Cerebral protection during moderate hypothermic circulatory arrest: histopathology and magnetic resonance spectroscopy of brain energetics and intracellular pH in pigs. J. Thorac. Cardiovasc. Surg. 112: 1073-1080, 1996.
13) Koja K., Kuniyoshi Y., Iha K., Akasaki M., Miyagi K., Shimoji, ? Kugai T. and Kusaba A.: Selective cerebral perfusion for arch aneurysm surgery. Jpn. Ann. Thorac. Surg. 13: 492-496, 1993 (in Japanese).
14) Schepens A.M., Defaw A.M., Hamerlijinck H.M., Geest R.G., and Vermeulen E.E.: Surgical management of thoracoabdominal aortic aneurysms by simple crossclamping. Riskfactors and late results. J. Thorac. Cardiovasc. Surg. 107: 135-142, 1994.
15) Cox G.S., O'Hara P.J., Hertzer N.R., Piedmonte M.R., Krajewski L.P. and Beven E.G.: Thoracoabdominal aneurysm repair: a representative experience. J. Vasc. Surg. 15: 780-788, 1992.
16) Wojewski P.A.: Spinal cord protection during thoracoabdominal aneurysm resection. J. Thorac. Cardiovasc. Surg. 109: 1244-1246, 1995.
17) Ohmi M., Osaka K., Sadahiro M., Shoji Y., Togo, T. and Tabayashi K.: Staged operation for aneurysms of the entire aorta: reports of four cases. J. Jpn. Thorac. Surg. 42: 2285-2291, 1994 (in Japanese).