琉球大学学術リポジトリ

[症例報告]Apocrine Carcinoma of the Breast : A Case Report with Immunohistochemical Study

メタデータ	言語: English 出版者: 琉球医学会 公開日: 2010-07-02 キーワード (Ja): キーワード (En): apocrine carcinoma, breast, immunohistochemical study, case report 作成者: Kuninaka, Koichi, Miyaguni, Takao, Deguchi, Shigeru, Shimoji, Hideaki, Muto, Yoshihiro, Nohara, Masashi メールアドレス: 所属:
URL	http://hdl.handle.net/20.500.12000/0002016215

Apocrine Carcinoma of the Breast: A Case Report with Immunohistochemical Study

Koichi Kuninaka[1], Takao Miyaguni[1], Shigeru Deguchi[1]
Hideaki Shimoji[1], Yoshihiro Muto[1] and Masashi Nohara[2]

[1] *The First Department of Surgery, Faculty of Medicine, University of the Ryukyus, and*
[2] *Daido Hospital, Okinawa, Japan*

(Received on August 15, 2000, accepted on October 24, 2000)

ABSTRACT

A case of apocrine carcinoma of the breast in a 66-year-old Japanese woman is herein reported. The patient was admitted to our University Hospital for a palpable left breast mass on January 17, 2000. The tumor was mildly painful and was palpated as a 2 × 3 cm oval, hard mass with relatively well-circumscribed margins located in the outer upper quadrant of the left breast. The tumor markers (CEA, CA15-3, TPA, NCC-ST-439, BBC225) were all within the normal ranges. Mammography revealed a 2 cm-opaque mass with intratumoral scattered microcalcifications and relatively well-defined margins. MR images showed a 2 cm oval mass. The tumor showed a high intensity mass on the T1-weighted image and a low intensity mass on the T2-weighted image. A needle biopsy revealed apocrine carcinoma. The patient underwent Auchincloss' s operative procedure. The tumor measured 1.2 cm in the greatest dimension, and appeared to be solid, gray-whitish and well-defined. The tumor showed typical histologic features of apocrine carcinoma. Immunohistochemically, the tumor showed a positive expression for AR, PR, and GCDFP-15, but a negative expression for ER, bcl-2 and p53. The tumor was classified to be Stage I (T2, N0,M0). *Ryukyu Med. J., 20(2)81~84, 2001*

Key words: apocrine carcinoma, breast, immunohistochemical study, case report

INTRODUCTION

Apocrine carcinoma is a well-recognized type of breast carcinoma[1,2] which is extremely rare, accounting for only 0.3 to 1.0 % of all primary breast carcinomas[2-5], and thus is seldom encountered during the career of the average surgeon. Therefore, it is important to report rare cases of this tumor so that more information can be gathered to both assess and diagnose such cases and also better predict tumor behavior. This report concerns a case with unique histologic features and also discusses certain interesting clinical aspects.

CASE REPORT

A 66-year-old Japanese woman presented with a one-year history of a palpable left breast mass. Her medical history revealed that she had been administered antihypertensive agents for 8 years. Her family history disclosed many instances of cancer (mother; lung cancer, sister; pancreatic cancer and brother; hepatocellular carcinoma). She was referred to our University Hospital due to a left painful breast mass on January 17,2000. The tumor was mildly painful and was palpated as a 2 × 3 cm-dumb-bell like, hard mass, with relatively well-cirumscribed margins located in the outer upper quadrant of the left breast. The tumor was mobile and not adherent to the pectoralis major muscle. The skin overlying the tumor appeared normal. There was no palpable lymph node enlargement in both axillas. The laboratory findings showed a serum total cholesterol of 256 mg/dl (normal; 124 - 220) and a serum triglyceride of 167 mg/dl (normal; 35 - 180). All tumor markers including CEA, TPA, CA15-3, BBC225 and NCC-ST-439 were within the normal limits. Moreover, both the serum estrogen receptor (ER) and progesterone receptor (PR) were negative.

Mammography showed a 2.0 cm-oval opaque mass with intratumoral scattered microcalcification. The tumor margins were relatively well-defined (Fig. 1). US (ultrasonography) revealed a 2 cm- hypoechoic mass with a heterogenous internal pattern. MRI revealed a heterogenous mass with ill-defined margins. It was depicted as a high intensity tumor on the T1-weighted MR image and a low in tensity tumor on the T2-weighted MR image (Fig. 1).

A core-needle biopsy was performed. Pathologically, the tumor showed apocrine carcinoma of the breast. The patient underwent Auchincloss' operative procedure (a mastectomy and nodal dissection with a preservation of

Table 1 Immunohistochemical characteristics of apocrine carcinoma of the breast

	AR	ER	PR	bcl-2	p53	GCDFP-15
Gatalica's cases	80%	60%	40%	50%	50%	55%
Our case	+	−	+	−	−	+

The percentage of positive cases is shown.

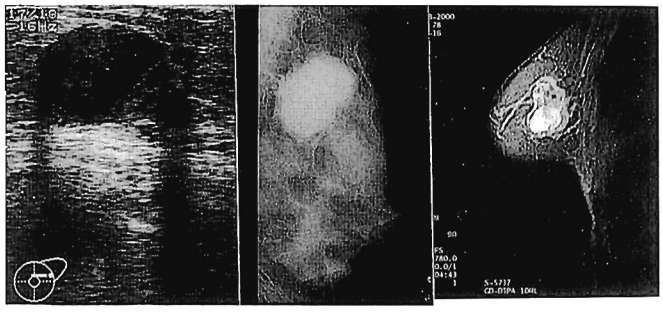

Fig. 1 An ultrasonograph of the left breast showing a hypoechoic mass lesion (left), a mammograph revealing an oval tumor lesion (middle) and a T1-weighted MRI demonstrating a high intense, dum-bell-shaped tumor lesion (right).

the pectoralis major and minor muscles). This apocrine carcinoma was clinically T2 N0 M0 (Stage I). The patient had an uneventful postoperative course and was discharged three weeks after the operation.

Grossly, the tumor on a cut section appeared granular, gray-whitish and the margin was well-defined. Histologically, the tumor was composed of neoplastic epithelial cells arranged in a papillary structure. The tumor consisted of columnar or polygonal epithelial cells with fine granular eosinophilic cytoplasm with apical budding of the cytoplasm, thus indicating an apocrine discharge of granules (Fig. 2). No lymph node metastasis was observed.

We evaluated this apocrine carcinoma using an immunostaining method for steroid hormone receptors (estrogen, progesterone, androgen), p53, bcl-2 and GCDFP-15. Paraffin embedded tissue and avidin-biotin peroxidase complex were used. As a result, the immunostaining for androgen receptor (AR), progesterone receptor (PR) and GCDFP-15 were all considered to be positive, while that for estrogen receptor (ER), bcl-2 and p53 were evaluated to be negative (Fig. 3) (Table 1).

DISCUSSION

Apocrine carcinomas analogous to sweat gland neoplasms have been reported to arise from the breast. Carcinoma of this type is rare with its reported prevalence ranging from only 0.3% to 1%[2-5]. The morphological criteria of apocrine carcinoma according to several investigators[2, 3, 6, 7] are: 1) ample eosinophilic cytoplasm, 2) a variable number

Fig. 2 Microphotographs of the tumor showing neoplastic epithelial cells arranged in papillary structures (top; HE, ×10) and columnar or polygonal epitheial cells with both a fine granular eosinophilic cytoplasm and apical budding (bottom, HE, ×50).

of granules (PAS positive after diastase digestion), 3) an expression of GCDFP-15, 4) the formation of apical budding. At our hospital, apocrine carcinoma was diagnosed based on these criteria.

Apocrine carcinoma was first termed "juvenile carcinoma" because it was noted in young women[8]. Nevertheless, the age distribution of women with apocrine carcinoma reported in the literature does not appear to differ from that of women with common invasive ductal carcinoma[9, 10]. The age of our patient was similar to that of other patients reported in the literature.

Most patients present with a palpable mass, ranging from 1.5 cm to 5.5 cm in diameter[11]. It is widely accepted that mammography is the most sensitive diagnostic modality for detecting breast carcinoma. Kopans *et al*[12] drew our attention to the mixed form of diffusely scattered calcification associated with breast carcinoma with apocrine features, wheres it is generally accepted that diffusely scattered microcalcifications are associated with benign disease, and clusters of microcalcifications are associated with malignant disease. Otherwise, the mammographic patterns of apocrine carcinoma do not differ from those of common invasive

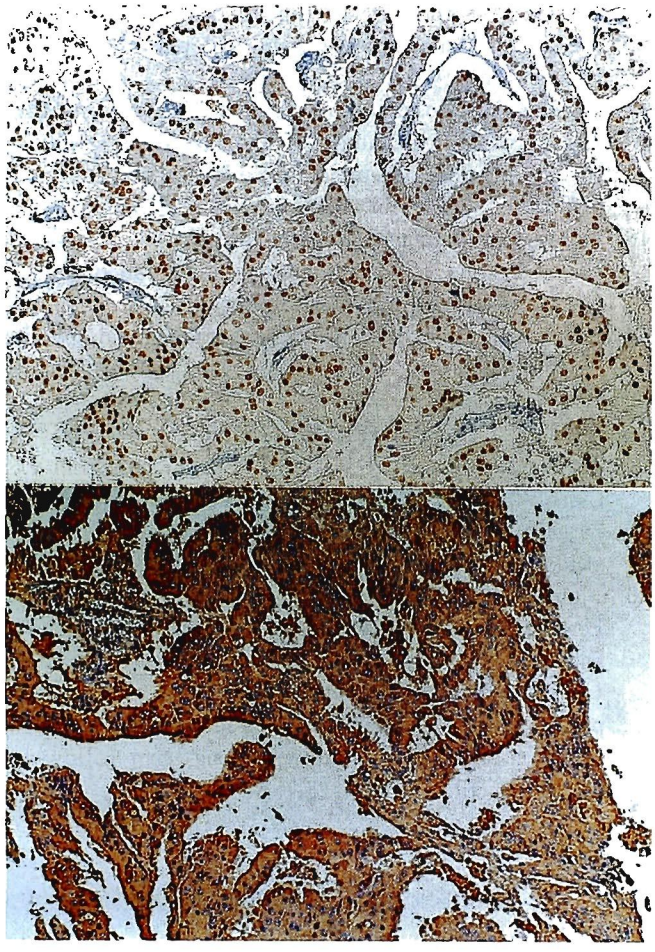

Fig. 3 Microphotographs showing the findings of immunostaining for AR (top) showing a strong nuclear positivity and for GCDFP-15 (bottom) showing cytoplasmic positivity (×25).

ductal carinomas[11, 13, 14]. Unexpectedly, to our knowledge there have been few reports using CT and MRI studies to make a definite diagnosis of apocrine carcinoma. Based on our experience, CT and MRI examinations are not able to differentiate such apocrine carcinoma from common invasive ductal carcinoma.

The prognosis of apocrine carcinoma has been reported to be equal to that of common invasive ductal carcinoma. Nevertheless, because of the rarity of apocrine carcinoma, no definite conclusions have yet been made[1, 3]. Due to recent advances in immunohistochemical techniques, several attempts are currently been made to overcome the difficulties in assessing the prognosis based on conventional histology alone. An association of apocrine carcinoma to steroid receptor or oncoprotein expression may provide valuable information regarding the biological behavior of apocrine carcinoma. Morpholgically, apocrine carcinoma is thought to represent a rare, specific variety of common invasive ductal carcinoma with unique hormone response patterns and thus, the apocrine features correlate with the amount of GCDFP-15 released by neoplastic cells[15, 16] and receptor levels of androgen (AR), but not estrogen (ER). The tumor in our case showed a positive expression for AR, PR and GCDFP-15, but a negative expression for ER, bcl-2 and p53 (Table 1). It is therefore worth investigating the presence of AR together with ER and progesteron receptor (PR) in order to select both the most appropriate therapy regimen and also to determine the prognostic outcome in breast cancer. Moreover, the c-erbB-2 oncogene expression has also been reported to be associated with aggressive breast cancer[17-20].

In conclusion, the present case report and a brief literature review supports the view that apocrine carcinoma of the breast is a rare tumor with characteristic histological features. There are still no distinctive physical and diagnostic findings that would allow a clinician to suspect a diagnosis of apocrine carcinoma. Furthernore, whether or not the prognostic outcome of apocrine carcinoma is identical to that of common invasive ductal carcinoma still remains unresolved.

ACKNOWLEDGEMENTS

We thank the pathologists and medical technologists at our University Hospital for providing surgical specimens and their excellent technical assistance and Mr. Brian Quinn for his comments on this manuscript.

REFERENCES

1) Haagensen C.D.: Disease of the breast. 2nd ed., Philadelphia., W.B. Saunders Co., 1971.
2) Azzopardi J.: Problems in breast pathology. London., W.B. Saunders Co., 1979.
3) Mossler J., Barton T., Brinkhons A., MaCarthy K., Moylan J. and MaCarthy K.Jr.: Apocrine differentiation in human mammary carcinoma. Cancer 46: 2463-2471, 1980.
4) Frable W.J. and Kay S.: Carcinoma of the breast: histologic and clinical features of apocrine tumors. Cancer 21: 756-763, 1968.
5) Yoshida K., Inoue M., Furuta S., Sakai R., Imai R., Hayakawa S., Fukatsu T., Nagasaka T. and Nakashima N.: Apocrine carcinoma vs. apocrine metaplasia with atypia of the breast. Use of aspiration biopsy cytology. Acta Cytol. 40: 247-251, 1996.
6) Mazoujian G., Bodian C., Haagensen D.E. and Haagensen C.D.: Expression of GCDFP-15 in breast carcinoma. Relationship to pathologic and clinical factors. Cancer 63: 2156-2161, 1989.
7) Schauburg-Lever G. and Lever W.F.: Secretion from human apocrine glands: An electron microscope study. J. Invest. Dermatol. 64: 38-41, 1975.
8) Divitt R. and Stewart F.: Breast carcinomas in children. J.A.M.A. 195: 388-390, 1966.
9) Abati A., Kimmel M. and Rosen PP.: Apocrine mammary

carcinoma. Am. J. Clin. Pathol. 94: 371-377, 1990.
10) Eusebi V., Millis R., Cattani M., Bossolati G. and Azzopardi J.: Apocrine carcinoma of the breast. Am. J. Pathol. 123: 532-541, 1986.
11) Gilles R., Lesnik A., Guinebretiere J-M, Tardivon A., Masselot J., Contesso G. and Vanel D.: Apocrine carcinoma: Clinical mammographic features. Radiology 190: 495-497, 1994.
12) Kopans D., Nguyen P., Koerner F., White G., McCarthy K.A., Hall D.A., Mrose H., Gardenosa G and File-Spellman E.: Mixed form, diffusely scattered calcifica-tions in breast cancer with apocrine metaplasia. Radiology 177: 807-811, 1990.
13) Sickles E.: Mammographic features of 300 consecutive nonpalpable breast cancers. A. J. R. 146: 661-663, 1986.
14) Stomper P.C., Connolly J.L., Meyer J.E. and Harris J.R.: Clinical occult ductal carcinoma in situ detected with mammography: Analysis of 100 cases with radiologic-pathologic correlation. Radiology 172: 235-241, 1989.
15) Eusebi V., Magalhaes F. and Azzopardi J.G.: Pleomorphic lobular carcinoma of the breast: An aggressive tumor showing apocrine differentiation. Hum. Pathol. 23: 655-662, 1992.
16) Walford N. and Ten Velden J.: Histocytoid breast carcinoma: An apocrine varient of lobular carcinoma. Histopathology 14: 515-522, 1989.
17) Alexiev B., Boschnakova Z. and Prokopanov Ch.: The aprocrine carcinoma of the breast. A cytological, immunohistochemical and ultrastructural study of 6 cases. Zentralbl. Pathol. 140: 129-134, 1994.
18) Gatalica Z.: Immunohistochemical analysis of apocrine breast lesions. Consistent over-expression of androgen receptor accompanied by the loss estrogen and progesteron receptors in apocrine metaplsia and apocrine carcinoma in situ. Pathol. Res. Pract. 193: 735-758, 1997.
19) Yokota T., Imamura M., Teshima S., Suzuki H., Tezuka F., Kikuchi S., Kunii Y. and Yamauchi H.: C-erbB-2, p53 protein expression and steroid hormone receptors in breast carcinomas: An immunohistochemical study. Anticancer Res. 19(5b): 4007-4012, 1999.
20) Mauri F.A., Maisonneuve P., Veronese S., Aldovini D., Ferrero S., Cozzaglio F., Dalla-Palma P., Galligioni E. and Barbareschi M.: Prognostic value of estrogen receptor status can be improved by combined evaluation of p53, Bcl-2 and PgR expression: An immunohistochemical study on breast carcinoma with long-term follow-up. Int. J. Oncol. 15: 1137-1147, 1999.